

<http://scielo.sld.cu/scielo.php?script=sci.arttext&pid=S0864-21762009000100012>

7. Zielonka J, Joseph J, Sikora A, Hardy M, Ouari O, Vasquez-Vivar J, et al. Mitochondria-targeted triphenylphosphonium-based compounds: syntheses, mechanisms of action, and therapeutic and diagnostic applications. *Chem Rev*. 2017;117:10043–120. <http://dx.doi.org/10.1021/acs.chemrev.7b00042>. <https://www.ncbi.nlm.nih.gov/pubmed/28654243>
8. Martins Regina HG, Bueno Elaine C, Fioravanti MP. Síndrome de Rubinstein-Taybi: anomalias físicas, manifestações clínicas e avaliação auditiva. *Rev Bras Otorrinolaringol*. 2003;69:427–31. <http://www.scielo.br/scielo.php?script=sci.arttext&pid=S0034-72992003000300019>
9. Villani A, Greer MC, Kalish JM, Nakagawara A, Nathanson KL, Pajtler KW, et al. Recommendations for cancer surveillance in individuals with RASopathies and other rare genetic conditions with increased cancer risk. *Clin Cancer Res*. 2017;23:e83–90.

<http://dx.doi.org/10.1158/1078-0432.CCR-17-0631>
<http://www.ncbi.nlm.nih.gov/pubmed/28620009>

Igor Romaniouk*, Antonio Romero, Paula Runza, Carmen Nieto, Ricardo Mouzo, Fernando Simal

Servicio de Nefrología, Hospital el Bierzo, Ponferrada, León, Spain

* *Corresponding author.*

E-mail address: igor9843@gmail.com (I. Romaniouk).

2013-2514/© 2017 Sociedad Española de Nefrología. Published by Elsevier España, S.L.U. This is an open access article under the CC BY-NC-ND license (<http://creativecommons.org/licenses/by-nc-nd/4.0/>).

<https://doi.org/10.1016/j.nefro.2018.05.001>

Hepatotoxicity associated with eculizumab in a patient with atypical hemolytic uremic syndrome

Hepatotoxicidad asociada con eculizumab en un paciente con síndrome urémico hemolítico atípico

Dear Editor,

Monoclonal C5 anti-body eculizumab, approved for aHUS treatment, is reported as efficient and safe. The long-term safety of eculizumab is promising but remains uncertain. Although hepatic side effects have been reported in pediatric cases after eculizumab treatment,^{1,2} hepatotoxicity in association with eculizumab has not been reported in adults previously. Herein, we presented an adult case of aHUS in whom hepatotoxicity was observed following eculizumab treatment.

A 39-year-old male with blurred vision and headache for three days was referred to our center with the diagnosis of thrombotic microangiopathy (TMA). On his physical examination blood pressure was 220/110 mmHg and grade 3 hypertensive retinopathy was determined. Laboratory tests revealed elevated serum creatinine and lactate dehydrogenase (LDH) levels, thrombocytopenia, schistocytes on peripheral blood smear, normal hepatic enzyme levels, negative direct coombs test, mildly decreased C3 (88.8 mg/dL) and normal C4 level (9.5 mg/dL). Serological tests were negative. Kidneys were normal on ultrasonography. He had varicocele operation a month ago, and creatinine was 0.9 mg/dL. His mother was on hemodialysis with unknown etiology for 8 years. Plasma exchange (PE) was initiated for TMA. Blood pressure was controlled with intensive anti-hypertensive

treatment consisted of amlodipine, carvedilol, ramipril and alpha-methyldopa. There was no left ventricular hypertrophy finding on echocardiography, and we excluded malignant hypertension in our case who was previously normotensive. On 7th day, ADAMTS13 activity was reported as normal (59%, reference range 40–130% activity). A total of 19 PE sessions were performed with the diagnosis of aHUS. Serum LDH level and thrombocytopenia were improved whereas kidney function was not. Renal biopsy, performed because of kidney dysfunction, revealed fibrin deposits in capillary lumina of glomerulus and mesangiolytic changes that confirmed TMA. He did not require hemodialysis during follow-ups. We decided to start eculizumab with the diagnosis of aHUS and persistent renal dysfunction. Eculizumab was initiated 900 mg weekly for 4 weeks with appropriate administration under antibiotic prophylaxis, after immunization with vaccines. Transaminase levels increased at 3rd day after the third dose and the subsequent dose was delayed (Fig. 1). Further investigations excluded other causes of hepatocellular injury such as viral, autoimmune or toxic. Ultrasonography showed only mild hepatomegaly and hepatosteatosis. Serum bilirubin and INR levels were within normal ranges. Transaminase levels decreased after 12 day interval, and he received the 4th dose even though ALP and GGT levels were mildly elevated. Then, enzyme levels markedly re-elevated, and eculizumab was withdrawn because of fulminant hepatitis risk. Enzyme levels

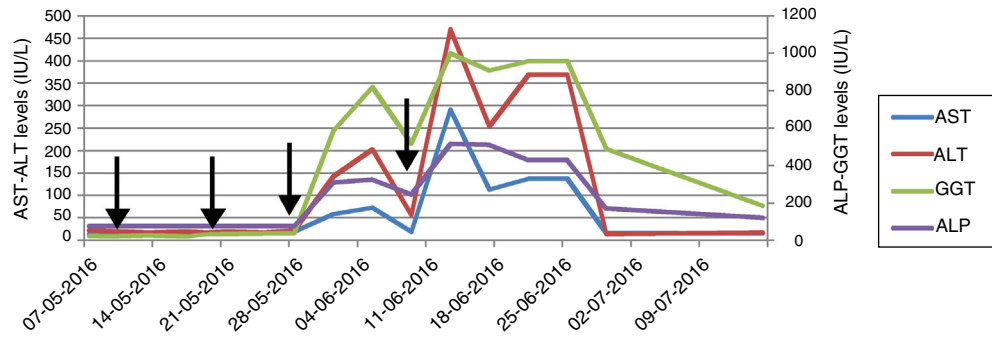


Fig. 1 – Hepatic enzymes (AST, ALT, ALP and GGT) levels were presented during eculizumab treatment. Consecutive eculizumab doses were marked with arrows.

returned to normal ranges within 20 days. Laboratory changings were showed in Table 1. On follow-ups, he had no TMA relapse. However, his creatinine level remained high without any uremic symptoms. He continues to our outpatient clinic on anti-hypertensive treatment and free of TMA event with normal liver enzyme levels.

Drug-induced liver injury (DILI) is a leading cause of acute liver failure and has clinical manifestations ranging from asymptomatic liver enzyme derangement to fulminant liver failure. The pattern of injury is classified as hepatocellular, cholestatic and mixed and R-ratio is used to identify the pattern.^{3,4} Although withdrawal of suspected drug is recommended, the importance of the therapy might be considered before cessation. The drug should be stopped in the course of elevation in ALT more than 8 times of upper normal limit (UNL), with or without derangement in bilirubin, albumin, INR.⁵ The vast majority of the subjects recover after discontinuing; however, knowledge about using the suspected drug again is limited. We considered discontinuing because of marked elevation in ALT more than 8 times of UNL after the subsequent dose. Liver enzymes recovered within days after cessation.

Knowledge is limited among aHUS patients and there were no reports of hepatotoxicity with eculizumab in PNH studies.^{6–8} A recent study reported DILI in 5 of 11 children treated with eculizumab for aHUS in a single center.¹ Elevation was seen on 10–29 days following eculizumab and resolution was within 14–21 days. Neither of presented cases had elevated enzyme levels prior to treatment. One patient discontinued because of marked elevation with subsequent infusion

and clinical symptoms of tender hepatomegaly and jaundice. Transient elevation in transaminase levels were reported under eculizumab treatment.^{2,9} These studies suggested that hepatocellular injury might be related to pre-existing ongoing TMA before treatment initiation, and enzymes tended to normalization after treatment with resolving TMA. Opposite to findings of these studies, Hayes' study and our patient had normal liver enzyme levels at the time of diagnosis and before eculizumab treatment. Hepatotoxicity was observed on the 3rd day after the 3rd dose of eculizumab and because it was the only alternative option we had to administer the consecutive dose that caused markedly elevation. These findings in the present case supported hepatotoxicity and diagnosis of mixed type DILI was considered. We did not consider other medications including prophylactic antibiotic were associated with DILI because similar pattern of injury was occurred with consecutive eculizumab administration. Due to fulminant hepatitis risk and insufficient knowledge about hepatotoxicity in adults in the literature, we stopped eculizumab, and decided to initiate PE if TMA relapse. Liver enzymes normalized within 20 days after cessation.

Mechanism of hepatic injury associated with biologic agents like eculizumab is not fully understood. There are several explanations like anti-body mediated injury, blockage of C5 which is effective in hepatic regeneration and defense reactions.¹

Although reports are signed out that eculizumab is a safe and efficient treatment option for aHUS, hepatotoxicity risk should be taken into consideration as a potential adverse effect. To our knowledge, this is the first adult case report

Table 1 – Laboratory findings at presentation and during eculizumab treatment.

	Presentation	1st dose	After the 3rd dose	After the 4th dose	20 day after cessation	Last visit
Serum creatinine (mg/dL)	5.1	4.3	4.2	4.3	3.8	2.9
Hemoglobin (g/dL)	8.7	9	9.9	10.2	10.1	12
Thrombocyte (k/ μ L)	49	195	252	282	246	264
LDH (NR 125–243 IU/L)	1152	298	270	285	260	236
AST (NR 13–30 IU/L)	14	17	73	291	16	16
ALT (9–57 IU/L)	23	21	147	471	32	44
ALP (NR 40–150 IU/L)	75	72	310	516	170	88
GGT (NR 12–64 IU/L)	46	44	586	1001	490	48

NR, normal range; LDH, lactate dehydrogenase; AST, aspartate aminotransferase; ALP, alkaline phosphatase; GGT, gamma glutamyl transferase.

of severe hepatotoxicity associated with eculizumab. Hepatic enzyme levels should be controlled in patients receiving eculizumab. Further reports including large data are required to evaluate hepatotoxicity risk of this novel agent.

Conflict of interest

The authors declare that they have no conflict of interest.

REFERENCES

- Hayes W, Tschumi S, Ling SC, Feber J, Kirschfink M, Licht C. Eculizumab hepatotoxicity in pediatric aHUS. *Pediatr Nephrol*. 2015;30:775–81, <http://dx.doi.org/10.1007/s00467-014-2990-5>.
 - Greenbaum LA, Fila M, Ardissino G, Al-Akash SI, Evans J, Henning P, et al. Eculizumab is a safe and effective treatment in pediatric patients with atypical hemolytic uremic syndrome. *Kidney Int*. 2016;89:701–11, <http://dx.doi.org/10.1016/j.kint.2015.11.026>.
 - Giordano C, Rivas J, Zervos X. An update on treatment of drug-induced liver injury. *J Clin Transl Hepatol*. 2014;2:74–9, <http://dx.doi.org/10.14218/JCTH.2014.00005>.
 - Haque T, Sasatomi E, Hayashi PH. Drug-induced liver injury: pattern recognition and future directions. *Gut Liver*. 2016;10:27–36, <http://dx.doi.org/10.5009/gnl15114>.
 - Tajiri K, Shimizu Y. Practical guidelines for diagnosis and early management of drug-induced liver injury. *World J Gastroenterol*. 2008;14:6774–85.
 - Brodsky RA, Young NS, Antonioli E, Risitano AM, Schrezenmeier H, Schubert J, et al. Multicenter phase 3 study of the complement inhibitor eculizumab for the treatment of patients with paroxysmal nocturnal hemoglobinuria. *Blood*. 2008;111:1840–7, <http://dx.doi.org/10.1182/blood-2007-06-094136>.
 - Hillmen P, Hall C, Marsh JCW, Elebute M, Bombara MP, Petro BE, et al. Effect of eculizumab on hemolysis and transfusion requirements in patients with paroxysmal nocturnal hemoglobinuria. *N Engl J Med*. 2004;350:552–9, <http://dx.doi.org/10.1056/NEJMoa031688>.
 - Hillmen P, Muus P, Röth A, Elebute MO, Risitano AM, Schrezenmeier H, et al. Long-term safety and efficacy of sustained eculizumab treatment in patients with paroxysmal nocturnal haemoglobinuria. *Br J Haematol*. 2013;162:62–73, <http://dx.doi.org/10.1111/bjh.12347>.
 - Fakhouri F, Hourmant M, Campistol JM, Cataland SR, Espinosa M, Gaber AO, et al. Terminal complement inhibitor eculizumab in adult patients with atypical hemolytic uremic syndrome: a single-arm, open-label trial. *Am J Kidney Dis*. 2016;68:84–93, <http://dx.doi.org/10.1053/j.ajkd.2015.12.034>.
- Aysegul Oruc^{a,*}, Yavuz Ayar^a, Berna Aytac Vuruskan^b, Abdulmecit Yildiz^a, Nimet Aktas^c, Mahmut Yavuz^a, Mustafa Gullulu^a, Kamil Dilek^a, Alparslan Ersoy^a
- ^a Department of Internal Medicine, Division of Nephrology, Uludağ University Medical School, Bursa, Turkey
^b Department of Pathology, Uludağ University Medical School, Bursa, Turkey
^c Cekirge State Hospital, Department of Nephrology, Bursa, Turkey
- * Corresponding author.
 E-mail address: aysegul@uludag.edu.tr (A. Oruc).

2013-2514/© 2017 Sociedad Española de Nefrología. Published by Elsevier España, S.L.U. This is an open access article under the CC BY-NC-ND license (<http://creativecommons.org/licenses/by-nc-nd/4.0/>).
<https://doi.org/10.1016/j.nefro.2018.04.004>

Case report: C3 glomerulopathy advancing atypical hemolytic uremic syndrome

Informe de caso: glomerulopatía C3 avanzando en síndrome urémico hemolítico atípico

Dear Editor,

We present a case report that initially diagnosed as C3 glomerulopathy (C3G) and later developed aHUS treated with eculizumab that improved renal function.

A previously healthy 25-year-old woman presented with leg swelling. Only mild pretibial edema was detected in her physical examination. Laboratory workup revealed that an erythrocyte sedimentation rate 110 mm/h, a serum creatinine

concentration of 2 mg/dL and albumin level of 2 g/dL. Urinalysis revealed a proteinuria of 9 g/day and microscopic hematuria.

Antinuclear antibodies, cytoplasmic antineutrophil cytoplasmic antibodies and perinuclear anti-neutrophil cytoplasmic antibodies were negative, serum C3 and C4 levels were normal. Kidney biopsy was performed. The biopsy contained 7 glomeruli which showed mesangial hypercellularity, segmental endocapillary proliferation, basement membrane