

Diagnostic Importance of Transesophageal Echocardiography for Detecting Patent Ductus Arteriosus (PDA) in a Puppy (Yavru Bir Köpekte Patent Duktus Arteriosus (PDA) Tespiti İçin Transözefagal Ekokardiyografinin Tanısal Önemi)

Zeki YILMAZ¹  Meriç KOCATÜRK¹ Hakan SALCI² Pınar LEVENT¹
Uygur CANATAN² Saim SAĞ³ Sümeyye GÜLLÜLÜ³

¹ Department of Internal Medicine, Faculty of Veterinary Medicine, Uludag University, TR-165059 Bursa - TURKEY

² Department of Surgery, Faculty of Veterinary Medicine, Uludag University, TR-165059 Bursa - TURKEY

³ Department of Cardiology, Medical School, Uludag University, TR-165059 Bursa - TURKEY

Article Code: KVFD-2016-16081 Published Online: 29.05.2016

Dear Editor;

Herein, we are presenting a case of patent ductus arteriosus (PDA) diagnosed by transesophageal echocardiography (TEE) in a puppy. Transthoracic echocardiography (TTE) is used as a traditional method during diagnostic work-up in patients with heart disease in human and veterinary medicine, but in some cases, it has a limitation to show the current problems due to low image resolution and anatomical disposition [1]. As compared with TTE, TEE offers superior visualization of dorsal cardiac structures due to close proximity of the esophagus to the dorsomedial heart with lack of intervening lung and bone. However, TEE procedure needs an anesthesia protocol as well as expensive equipment and experienced staff [1]. There are limited case presentations on the utility of TEE in the diagnosis of congenital heart defects.

A dog (Labrador, Male, 2 months of age, 5.2 Kg) was presented to Animal Hospital (Dep. of Internal Medicine, Faculty of Veterinary Medicine, Uludag University, Bursa) with a history of respiratory distress increasing with exercise for two days. The dog was alert and tachypneic (36 breath/min). Cardiac auscultation revealed a grade V/VI continuous machinery murmur over the pulmonic area. ECG revealed sinus tachycardia and left ventricular (LV) enlargement (R: 7.6 mV/lead II). Thoracic radiographs showed marked left-sided cardiomegaly with enlarged pulmonary arteries (PA) and minimal pulmonary edema. These findings suggested the presence of a congenital heart defect such as pulmonic stenosis, aortic stenosis, PDA, tetralogy of Fallot or dilated cardiomyopathy [1-4]. Routine hematological and biochemical analyses were non-specific.

With a TTE (Caris plus, Esoate, Italy), the 2-dimensional right parasternal, short-axis view revealed enlarged left

atrium (LA: 3.5 cm [1.0-1.6 cm]), whereas aortic diameter (Ao: 1.3 cm [1.0-1.5 cm]) was in reference range [1]. The M-mode echocardiogram showed the severe LV dilatation at diastole (4.48 cm [1.9-2.8 cm]) and systole (3.49 cm [1.1-1.9 cm]) as well as increased E-point to septal separation (1.22 cm [<0.6 cm]). A significant turbulence was observed on PA by color flow imaging, probably due to PA insufficiency, PA hypertension, aorticopulmonary window or PDA [1], but one of them could not be detected by TTE. Thus, to make a clear diagnosis, the use of TEE was decided (Vivid S5, General Electric). For this purpose, the dog was anesthetized with intravenous combination of ketamine HCl (10 mg/kg) (Alfamine®, Egevet, Turkey) and diazepam (0.5 mg/kg) (Diazem®, Deva, Turkey). The dog was intubated and vital parameters were controlled during TEE.

TEE revealed a severe mitral insufficiency at apical two-chamber view. Color flow imaging showed a marked turbulence over PA (Fig. 1A) and there was a connection (0.7 cm, Fig. 1B) between ascending Ao (Aa) and PA with a high flow velocity (Vmax: 2.97 m/s, gradient: 35.3 mmHg), indicating a large PDA [1,2]. Observed retrograde flow pattern on descending Ao supported the presence of blood access into Ao from PA, as well (Fig. 1C).

After TEE, the anaesthesia of the dog was maintained by 2% isoflurane for surgery. Left 4th intercostal thoracotomy incision was performed for vascular exploration. Ao and PA were dissected and then PDA was exposed and ligated with 0 no silk (Fig. 2) as reported earlier [3]. Routine thoracic closure and chest drainage were carried out. Postoperative analgesia (carprofen, 5 mg/kg, 1x1, 5 days) and antibiotherapy (cefazolin Na, 20 mg/kg, im, 2x1, 5 days) were completed.

PDA is classified as small (type 1), medium (type 2) and large (type 3 and 4). Type 3 PDA is related with left to



İletişim (Correspondence)



+90 224 2940809



zyilmaz@uludag.edu.tr

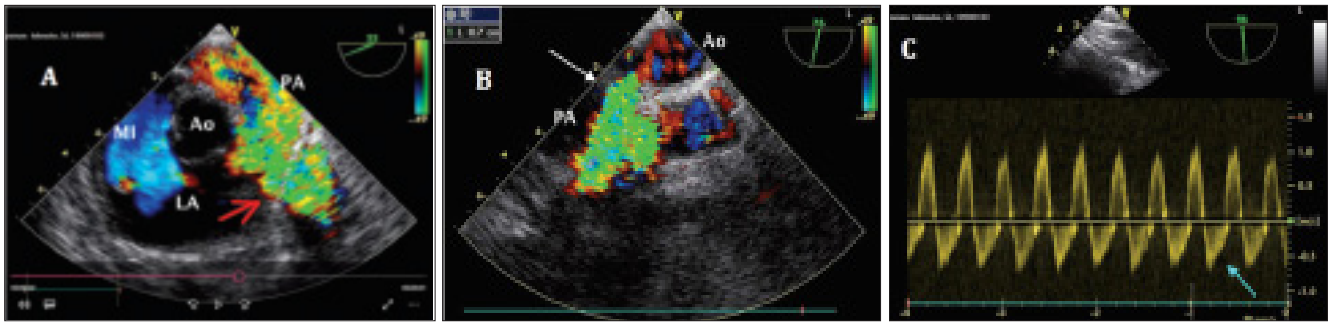


Fig 1. A: TEE short axis view demonstrating a significant turbulent flow (*mosaic color, red arrow*) in the pulmonary artery (PA), **B:** PDA jet and large defect (*white arrow*) between ascending aorta (Aa) and PA is seen at the 7 o'clock position, **C:** Retrograde flow in the descending aorta during diastole (*blue arrow*) revealing the presence of PDA

Şekil 1. A: TEE kısa ekseninde pulmoner arterde (PA) önemli türbülans akımı (*mozaik renk, kırmızı ok*) gösteriyor, **B:** Saat 7 pozisyonunda asending aorta (Aa) ve PA arasında PDA jeti ve büyük bir defekt (*beyaz ok*) görünüyor, **C:** Diyastol sırasında desending aortadaki ters yöndeki akım (*mavi ok*) PDA varlığını gösteriyor

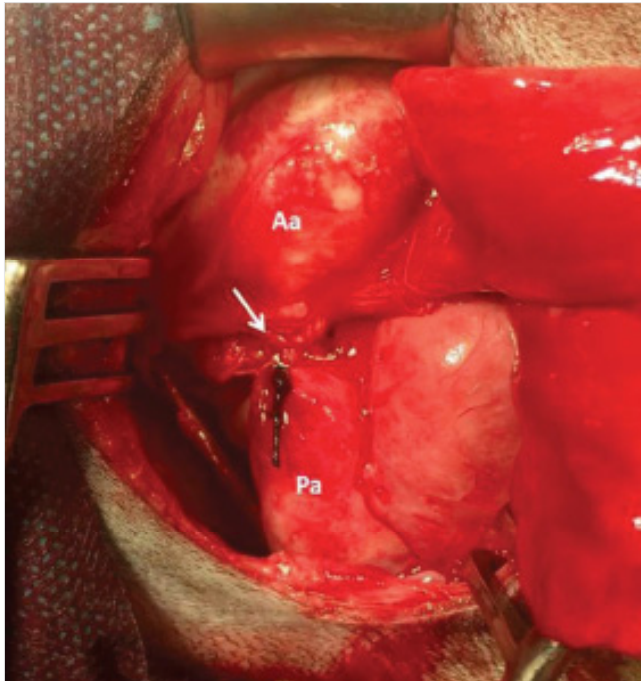


Fig 2. This perioperative view shows the localization of type 3 PDA. Aa: ascending aorta, Pa: pulmonary artery, arrow: ligated site

Şekil 2. Bu operasyon sırasındaki tip 3 PDA ile ilgili görünüm. Aa: asending aorta, Pa: Pulmonar arter, ok: ligature edilen yer

right shunt, but type 4 is related with right to left shunt, thus exhibiting cyanotic mucous membranes. Large PDA is sub-divided into those with (3a) and without (3b) congestive heart failure^[3]. Since our dog had a continuous murmur and thrill over the left thorax, marked left heart

enlargement, a significant increase in pulmonary vascular markings and R waves >5 mV/lead II, PDA was classified as type 3b. Surgery is recommended immediately in these cases^[2,3]. Thus, this dog was operated; defect between Aa and PA was corrected (*Fig. 2*) as reported earlier^[2]. Right after the operation, TTE revealed that high velocity flow pattern over the PA disappeared. Post-operative ECG showed lower R amplitude (4.6 mV/lead II) than the pre-operative value. These observations were compatible with the early cardiac responses (cardiac re-modelling) to new dynamics of the blood flow. Dog is still alive without cardiac medication for two months.

In conclusion, clinician should be kept in mind that respiratory problems might be due to congenital heart defects such as PDA in puppies, and in these cases comprehensive cardiological examinations including TEE utility should be performed. For symptomatic PDA, surgery should be definitive solution.

REFERENCE

- 1. Strickland KN, Oyama MA:** Congenital heart disease. In, Smith FWK, Tilley PA, Oyama MA, Sleeper MM (Eds): Manuel of Canine and Feline Cardiology. 5th ed., 220-238, Elsevier, 2016.
- 2. Yuan SM:** Surgical interventions of common congenital heart defects in dogs: A comprehensive review. *Kafkas Univ Vet Fak Derg*, 20, 473-480, 2014. DOI: 10.9775/kvfd.2013.10402
- 3. Kocaturk M, Salci H, Cetin M, Karapinar T, Yilmaz Z:** Echocardiographic diagnosis and surgical correction of aortopulmonary window in a Belgian Shepherd Dog (Malinois). *Ankara Üniv Vet Fak Derg*, 62, 75-80, 2015. DOI: 10.1501/Vetfak_0000002661
- 4. Houghton HE, Ware WA:** Patent ductus arteriosus in dogs. *Iowa State Univ Vet*, 58 (2): 1-5, 1996.