

PostScript

LETTERS TO THE EDITOR

If you have a burning desire to respond to a paper published in *Thorax*, why not make use of our "rapid response" option?

Log on to our website (www.thoraxjnl.com), find the paper that interests you, and send your response via email by clicking on the "eLetters" option in the box at the top right hand corner.

Providing it isn't libellous or obscene, it will be posted within seven days. You can retrieve it by clicking on "read eLetters" on our homepage.

The editors will decide as before whether to also publish it in a future paper issue.

Unusual lung consolidation in SLE

Pulmonary manifestations of systemic lupus erythematosus (SLE) include acute lupus pneumonitis, chronic interstitial pneumonitis, diaphragmatic dysfunction, atelectasis, pulmonary vascular disease, upper airway dysfunction, and bronchiolitis obliterans.¹ Pneumonia due to infection also develops because infection is a major cause of death of patients with SLE.^{2,3} Here, we report a patient with SLE who suffered from an ambulatory lung consolidation devoid of pathogens.

A 61 year old woman with SLE had been treated with 10 mg prednisolone every other day since 1990 without deterioration in the disease. She had complained of cough, non-purulent sputum, and fever once or twice a month since September 1998 which resolved spontaneously within a few days. In October 1999 she was first admitted to hospital with a lung consolidation and an ambient faint infiltrate over the left S4 and S6b on the chest radiograph and computed tomographic (CT) scan (fig 1A, D). She had pancytopenia,

increased levels of C reactive protein and LDH, a high titre of anti-double strand DNA antibody, and decreased levels of complement titres. Analysis of bronchoalveolar lavage fluid and histopathological examination of trans-bronchial lung biopsy specimens showed an increased number of lymphocytes with a low CD4/CD8 ratio. The presence of neither microorganisms nor granulomas was confirmed. She was discharged because the consolidation was reduced (fig 1B, E). In March 2000 she had another bronchoscopic examination because of deterioration of the consolidation (fig 1C, F) but the results were the same as in 1999. For the purpose of further examination we conducted a partial lung resection. The affected lung tissue histopathologically showed a non-specific inflammatory nodule which consisted of lymphocyte dominant inflammatory cell infiltration, lymph follicle formation, fibrosis, fibrin exudation, a thickened alveolar septum, and collapsed alveoli without infectious microorganisms or malignant cells. Removal of the affected lung tissue resulted in improvement in symptoms and abnormal data.

Non-specific inflammatory nodules might occur as a complication of SLE, and a surgical intervention should be considered to diagnose and treat the disease.

A Nomura, Y Morishita, T Iijima, Y Ishii, H Satoh, T Sakamoto, Y Uchida, T Homma, M Ohtsuka, K Sekizawa

Department of Pulmonary Medicine, Institute of Clinical Medicine, University of Tsukuba, Tsukuba, Ibaraki, Japan

Correspondence to: Dr K Sekizawa, Department of Pulmonary Medicine, Institute of Clinical Medicine, University of Tsukuba, 1-1-1 Tennoudai, Tsukuba, Ibaraki 305-8575, Japan; kiyo-se@md.tsukuba.ac.jp

References

- 1 King TE Jr, Cherniack RM, Schwarz MI. The lungs and connective tissue diseases. In: Murray JF, Nadel JA, eds. *Textbook of*

respiratory medicine. Philadelphia: WB Saunders, 1994: 1850-72.

- 2 Jarrett MP, Santhanam S, Del Greco F. The clinical course of end-stage renal disease in systemic lupus erythematosus. *Arch Intern Med* 1983;143:1353-6.
- 3 Cervera R, Khamashta MA, Font J, et al. Morbidity and mortality in systemic lupus erythematosus during a 5-year period. A multicenter prospective study of 1000 patients. European Working Party on Systemic Lupus Erythematosus. *Medicine (Baltimore)* 1999;78:167-75.

Atypical mycobacterial infection, starvation and effect of BCG vaccination on tuberculin skin test

Wang *et al*¹ are right when they underline the need to adjust for confounding variables when analysing the results of a tuberculin skin test (TST) survey, but they are oversimplistic when, using surveys done in many countries worldwide, they study only the effect of the BCG vaccination on the TST results. The authors did not discuss the rate of atypical mycobacterial infection in a population, an important confounding factor that drives up the rate of tuberculous infection, because atypical mycobacteria crossreact with *Mycobacterium tuberculosis*. Unlike Wang *et al*, at least one TST survey included in the meta-analysis, done in Kenya,² adjusted for the rate of atypical mycobacterial infection. A study performed in the Netherlands on army recruits which double tested for both *M tuberculosis* and atypical mycobacteria showed that 48% of the reactors with indurations in the range 10-15 mm and 16% with indurations ≥ 10 mm were classified as false positive.³ There was no interaction between BCG and TST as long as the recruits were not BCG vaccinated. False positives were then excluded from the latent tuberculosis infection treatment.

Another confounding factor in this meta-analysis is pooling together TST results from surveys performed in populations during the post-war period of starvation⁴ with those from developed countries without considering the effect of a low calorie diet on the TST results. Only 3-4 months after BCG vaccination the rate of apparent TST conversion in malnourished children may be as low as 23% compared with 85% in well nourished children.⁵

The rate of atypical mycobacterial infection might therefore have been confused for the TST positivity due to BCG vaccination, while the effect of BCG vaccination on the rate of TST positivity was underestimated in starving populations.

The author did not need financial support to write this letter and does not have any material interest in the subject.

M-S Jalba

Public Health Epidemiologist, New York City Department of Health and Mental Hygiene Tuberculosis Control Program

Correspondence to: Dr M S Jalba, 17-15 Woodbine Street, Apartment 3L, Ridgewood, New York 11385, USA; msj@about.com

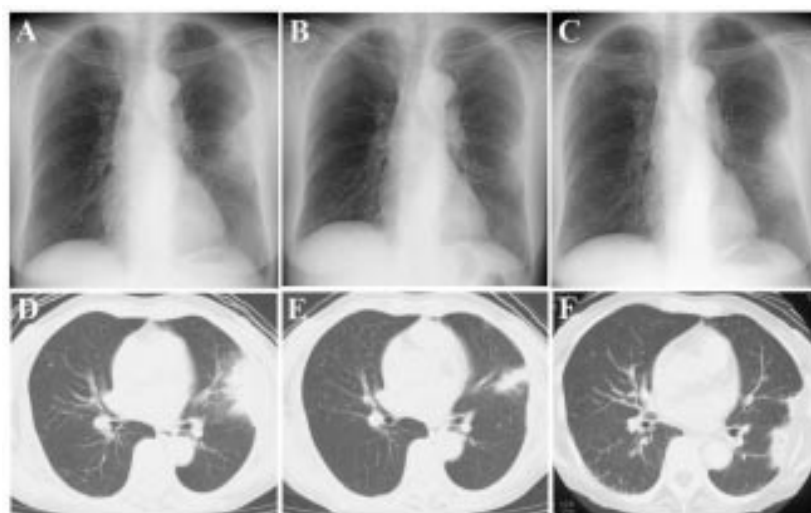


Figure 1 Chest radiograph and CT scan on first admission (A, D), at partial improvement (B, E), and on second admission (C, F) showing deterioration and improvement of a fan shaped patchy shadow on the pleura.

References

- 1 Wang L, Turner MO, Elwood RK, *et al*. A meta-analysis of the effect of Bacille Calmette Guerin vaccination on tuberculin skin test measurements. *Thorax* 2002;**57**:804–9.
- 2 Bosman MC, Swai OB, Kwamanga DO, *et al*. National tuberculin survey of Kenya, 1986–1990. *Int J Tuberc Lung Dis* 1998;**2**:272–80.
- 3 Bruins J, Gribnau JH, Bwire R. Investigation into typical and atypical tuberculin sensitivity in the Royal Netherlands Army, resulting in a more rational indication for isoniazid prophylaxis. *Tuberc Lung Dis* 1995;**76**:540–4.
- 4 Azbite M. Tuberculin survey in Ethiopia. *Kekkaku* 1992;**67**:539–44.
- 5 Chandra RK. Nutrition, immunity and infection: present knowledge and future directions. *Lancet* 1983;**1**:688–91.

Authors' reply

We would like to thank Dr Jalba for the thoughtful comments on our paper. As the prevalence of atypical mycobacterial infection was not systematically evaluated in the studies we reviewed, we could not integrate this into our analysis. From a practical point of view both BCG and non-BCG groups are likely to have similar exposures to atypical infection, and clinicians would not be able to assess routinely for such infections. Similarly, information on nutrition was not systematically available but, as a surrogate, we have looked at the impact of BCG as one moves further from the equator and found no differences in its impact. On the basis that malnutrition would be a greater confounder in studies done closer to the equator, this suggests that nutrition is not a significant factor in the sample size we have generated.

J M FitzGerald, M O Turner, L Wang,
M Schulzer, R K Elwood

Respiratory Division, Vancouver Hospital, 2775
Heather Street, Vancouver, BC, Canada V5Z 3J7;
markf@interchange.ubc.ca

Improving surgical resection rates in lung cancer without a two stop service

In 1998 the Papworth Thoracic Oncology Unit published their data from the first year of a two stop clinic. By this means they improved their surgical resection rates for patients with non-small cell lung cancer (NSCLC) from 10% to 25%.¹ This paper is quoted as the benchmark for surgical resection in the UK. In 1998 the surgical resection rate for patients with NSCLC in Hammersmith Hospitals Trust was 4.7% (three of 64 patients). In March 2000 we set up rapid access clinics to assess both patients with abnormal chest radiographs and urgent GP referrals. In accordance with the National Service Framework (NSF),² multidisciplinary team meetings (MDTM) between respiratory medicine, radiology, cardiothoracic surgery, oncology and palliative medicine were established.

From April 2000 inpatients and outpatients with a chest radiograph suspicious for lung cancer were referred directly from radiology to one of two rapid access clinics within the Trust. Local GPs, outpatient departments, and the emergency department also referred patients. There were no tertiary referrals. All patients were given appointments within the

2 week time period required by the NSF. Patients were told they were being investigated for an abnormal radiograph and would need further investigation with a CT scan and may require a bronchoscopy (FOB) and/or fine needle aspiration/biopsy (FNAB). Written information was given at that point regarding CT scanning, FOB, and FNAB. Staging and tissue diagnosis was completed within 2 weeks.

All results were reviewed in the MDTM and management plans were made and recorded. Following the MDTM, patients were reviewed in a joint clinic with the Macmillan nurse and introduced to either the oncologist or the thoracic surgeon. All data on every aspect of the patient's management were collected prospectively.

From 1 April 2000 to 31 March 2001 194 patients were seen (118 men). In 100 patients cancer was the most likely diagnosis (56 men and 44 women, mean age 67 years, range 26–95). Six patients declined further investigation. 94 (95%) patients had a finite histological diagnosis: 84 primary lung cancers, three secondary lung cancers, two carcinoid tumours, two Hodgkin's disease, and three mesothelioma.

Of the 84 patients with lung cancer, 14 had small cell carcinoma and 70 had NSCLC. Of the 70 patients with NSCLC, 20 (28.5%) were referred for thoracotomy (11 men, mean age 64 years, range 48–81). Nineteen patients (27% of NSCLC; 23% of the whole cohort) had a successful resection, 17 lobectomies (stages 5Ia, 3Ib, 3IIa, 3IIb and 3IIa) and two pneumonectomies (stages IIIb and Ia). One patient (5%) had a failed thoracotomy due to a cardiac event. In five cases (all Ia) the chest radiograph had been taken routinely before another operative procedure and three (Ia and IIIa) were routine outpatient radiographs in asymptomatic patients. There were no postoperative deaths. Two patients (pIIa) subsequently died at 9 and 11 months, respectively. Currently, the 1 year survival rate for the whole cohort of patients with proven lung cancer is 46%.

With no additional resources we have successfully implemented the lung cancer NSF and have significantly improved our surgical resection rates from 4.7% in 1998 to 27% of patients with NSCLC and 23% of our whole lung cancer cohort. This is equivalent to the benchmark series for surgical resection in the UK but, unlike that series, none of the patients were tertiary referrals.¹ Our large increase in resection rate was not due to a more aggressive surgical approach as 80% of the cases were stage IIB or better, and our failed thoracotomy rate of 5% is similar to other series.¹

We have shown that, without the resources to establish a two stop service we have still established a rapid and effective patient pathway culminating in an MDTM and joint clinic. This has produced resection rates considerably better than those previously achieved and a 1 year survival rate that compares very favourably with published UK survival figures.³

E F Bowen, J R Anderson, M E Roddie
Hammersmith & Charing Cross Hospitals NHS
Trust, Du Cane Road, London W12 0HN, UK;
fbowen@hhnt.org

References

- 1 Laroche C, Wells F, Coule R *et al*. Improving surgical resection rates in lung cancer. *Thorax* 1998;**53**:445–9.

- 2 Department of Health. *Improving the quality of cancer services*. London: Department of Health, 2000.
- 3 Janssen-Heijnen ML, Gatta G, Forman D, *et al*. Variation in survival of patients with lung cancer in Europe, 1985–1989. *Eur J Cancer* 1998;**34**:2191–6.

Publication of complex dataset

In the April 2002 issue of *Thorax* we published a paper on airway inflammation, basement membrane thickening and bronchial hyperresponsiveness in asthma.¹ In this study we examined the effects over 12 months of inhaled corticosteroid therapy on reticular basement membrane thickening in asthmatic airways and how this may influence airway hyperresponsiveness.

Shortly before, at the end of 2001, we also published a paper in the *American Journal of Respiratory and Critical Care Medicine*² which dealt with the baseline data on reticular basement membrane thickness for the same group of patients. The analysis dealt with the relationship between reticular basement membrane thickness, fixed airflow limitation, and a novel test of airway distensibility.

The existence of the respective papers was made clear to and discussed with the respective editors during each editorial process. The review process was long and exhaustive, continuing over many months. Mainly because of the temporal overlap of the two review processes, the paper in the *American journal* is not referenced in the *Thorax* paper.

Because of the increased sensitivity about potential for duplicate publication,^{3,4} we wish to make clear to the *Thorax* readership the existence of the two papers from the same study, although the overlap between them is small and explicit, and the analyses contained within each quite distinct. With hindsight, the joint source of these data should have been acknowledged in the published paper.

E H Walters

Department of Clinical Sciences, University of
Tasmania Medical School, Hobart, Tasmania
7001, Australia; haydn.walters@utas.edu.au

References

- 1 Ward C, Pais M, Bish R, *et al*. Airway inflammation, basement membrane thickening and bronchial hyperresponsiveness in asthma. *Thorax* 2002;**57**:309–16.
- 2 Ward C, Johns DP, Bish R, *et al*. Reduced airway distensibility, fixed airflow limitation, and airway wall remodeling in asthma. *Am J Respir Crit Care Med* 2001;**164**:1718–21.
- 3 Tobin MJ. AJRCCM's policy on duplicate publication. *Am J Respir Crit Care Med* 2002;**166**:433–7.
- 4 Editorial. Notice of duplicate publication. *Thorax* 2002;**57**:6.

Successful treatment of BALT lymphoma with combined chemotherapy

Primary pulmonary lymphoma arising from mucosa- or bronchus-associated lymphoid tissue (MALT or BALT) is a rare disease.^{1,2} We report a 30 year old man with low grade B cell BALT lymphoma who presented with a bulky mass in the lung and was treated successfully with cyclophosphamide, doxorubicin, vincristine and prednisone (CHOP) combined chemotherapy.

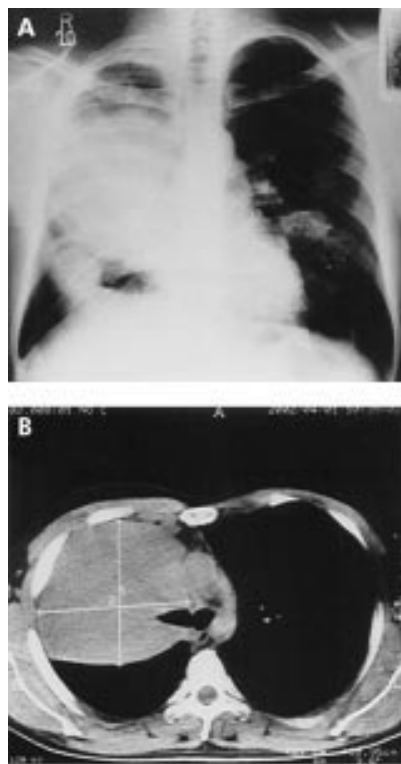


Figure 1 (A) Posteroanterior chest radiograph showing a bulky mass in the right lung, a smaller mass in the lower zone of the right lung, and heterogeneous infiltration in the middle zone of the left lung. (B) CT scan of the chest showing a bulky mass in the right lung.

The patient was admitted with a dry cough, shortness of breath, back pain, and progressive infiltrates on chest radiographs. He had no history of risks for BALT lymphoma.^{1,3,4} No rash or lymphadenopathy or organomegaly was detected. A CT scan of the chest showed a right mid lung bulky mass with a diameter of 10.9 × 10.6 cm and infiltrations in both lung fields (fig 1). A transbronchial biopsy specimen was compatible with low grade (B cell lymphoplasmacytoid type) lymphoma. Immunohistochemical examination showed a monoclonal membrane surface κ light chain positive. The patient underwent combined chemotherapy (CHOP) which was repeated every 3 weeks. He tolerated the treatment without difficulty, his symptoms improved, and CT scans after completion of six courses of treatment showed a marked reduction in the lesions in both lung fields (fig 2).

BALT lymphoma shows an indolent course and remains localised for a prolonged period of time, with systemic dissemination occurring late in the clinical course.² Recommended treatment options include complete surgical resection, radiotherapy, or chemotherapy. The role of surgery in the management of primary lymphoma of the lung is twofold: (1) to obtain diagnostic tissue and (2) to obtain a therapeutic resection. In our case we used combined chemotherapy because surgical intervention is of limited use in patients with a large non-resectable lesion or bilateral lung disease.^{2,5}

We conclude that, in patients with a large or bilateral pulmonary BALT lymphoma, transbronchial or transthoracic biopsy and mediastinoscopy are useful diagnostic procedures

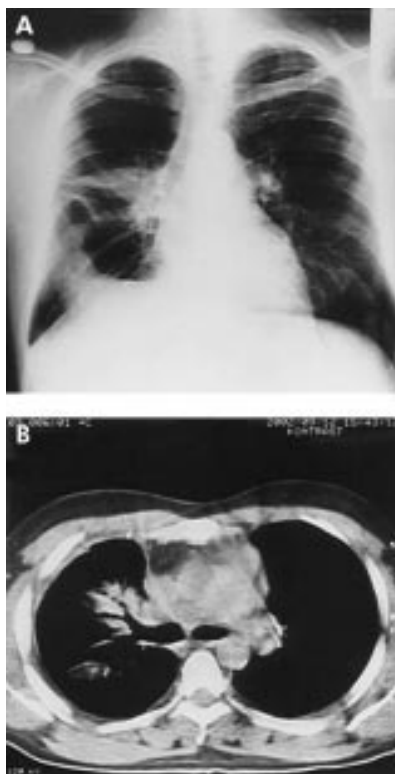

Figure 2 (A) Posteroanterior chest radiograph and (B) CT scan showing marked reduction in the lesions shown in fig 1.

for obtaining a definitive diagnosis⁵ and treatment with combined chemotherapy should be considered.

**R Ali, F Özkalemkaş, T Özçelik,
V Özkocaman, Ü Ozan, A Tunalı**

Division of Hematology, Department of Internal Medicine, Uludağ University School of Medicine, Bursa, Turkey

G Filiz

Department of Pathology, Uludağ University School of Medicine

O Gözü

Department of Chest and Tuberculosis, Uludağ University School of Medicine

Correspondence to: Associate Professor R Ali, Uludağ Üniversitesi Tıp Fakültesi Hematoloji Bilim Dalı, 16059 Görükle, Bursa, Turkey; ridvanali@uludag.edu.tr

References

- 1 **Kurosu K, Yumoto N, Furukawa M, et al.** Low-grade pulmonary mucosa-associated lymphoid tissue lymphoma with or without intraclonal variation. *Am J Respir Crit Care Med* 1998;**158**:1613–9.
- 2 **Ferraro P, Trastek VF, Adlakha H, et al.** Primary non-Hodgkin's lymphoma of the lung. *Ann Thorac Surg* 2000;**69**:993–7.
- 3 **Orchard TR, Eraut CD, Davison AG.** Non-Hodgkin's lymphoma arising in cryptogenic fibrosing alveolitis. *Thorax* 1998;**53**:228–9.
- 4 **Toyoshima M, Chida K, Sato A.** Antigen uptake and subsequent cell kinetics in bronchus-associated lymphoid tissue. *Respirology* 2000;**5**:141–5.
- 5 **King LJ, Padley AC, Watherspoon AC, et al.** Pulmonary MALT lymphoma: imaging findings in 24 cases. *Eur Radiol* 2000;**10**:1932–8.

Obstructive sleep apnoea can directly cause death

A 52 year old woman was referred for investigation of daytime somnolence. She complained of heavy snoring, unrefreshing disturbed sleep, and had fallen asleep while driving. She had an Epworth score¹ of 24/24, a history of hypertension controlled on losartan, had never smoked, and only took occasional alcohol. She had limited mobility as a result of her extreme obesity (168 kg) with a height of 1.58 m (BMI 67.3 kg/m²). Her chest was clinically clear (FEV₁ 1.8 l, FVC 2.3 l) and her serum bicarbonate level was 31 mmol/l, implying a degree of hypercapnia. She had a trace of oedema but no evidence of cardiac failure.

She was admitted 1 month later for a sleep study. Data collection included oximetry, pulse rate, movement and sound (SSI Visi-lab). At 04.30 hours the nursing staff found her lying dead across the bed. The oxygen saturation by pulse oximetry was 91% at the start of the night in a sitting position. Good data were obtained for the first 25 minutes of the study, the remainder being highly fragmented with values fluctuating between 90% and the instrument cut off level of 25%. The video showed a repeated but irregular pattern of apnoea, snoring, arousal, sitting up, falling asleep, and lying back into the supine position. From one such apnoea she failed to rouse sufficiently to resume breathing and suffered a cardiorespiratory arrest. Post mortem examination showed some coronary atheroma but, crucially, no occlusion, leading to the conclusion that the death was directly attributable to obstructive sleep apnoea (OSA). Lungs, liver and spleen showed some congestion consistent with the post mortem diagnosis of acute cardiorespiratory failure.

The coroner initially expressed concern that the patient was not being directly observed. After discussion it was accepted that a sleep test is not monitoring in the usual sense but is an exercise in data collection performed either in hospital or at home for reasons of organisational convenience.

This recorded death directly resulting from OSA in combination with severe obesity is unlikely to be unique and may be unusual only in that it was captured on the video recording. In such extreme cases recognising the component of OSA may be difficult as the oximetry recording is erratic rather than the familiar "saw tooth" waveform. A number of mechanisms associating OSA with increased morbidity and mortality have been proposed, significantly obesity and ventilatory failure² and vascular disease.³ However, this case demonstrates a causal connection.

Attributing unexpected deaths to cardiac events rather than to OSA may conceal a number of deaths directly caused by OSA.

S Pearce

University Hospital of North Durham, Durham DH1 5TW, UK; sarah.pearce@ndhcnt.northy.nhs.uk

P Saunders

Regional Medical Physics Department, University Hospital of North Durham, Durham DH1 5TW, UK

References

- 1 **Johns MW.** A new method for measuring daytime sleepiness: The Epworth sleepiness scale. *Sleep* 1991;**14**:540–1.
- 2 **Stradling JR.** *Handbook of sleep-related breathing disorders.* Oxford: Oxford University Press, 1993: 56–7.
- 3 **Lanfranchi P, Somers VK.** Obstructive sleep apnoea and vascular disease. *Respir Res* 2001;**2**:315–9.

Pancoast's syndrome as a result of metastatic renal cell carcinoma

Infections, lymphomas, and metastases¹⁻³ are unique causes of Pancoast's syndrome. The most common aetiological factor is non-small cell lung cancer (NSCLC). Pancoast's syndrome resulting from metastatic renal cell carcinoma (RCC) has not previously been reported. We present the case of a metastatic Pancoast tumour in the left lung in a patient who had previously undergone resection for RCC.

A 49 year old woman was admitted with a pain in the left shoulder radiating to the arm which had been present for several months, eight years after excision of the left kidney for clear cell RCC. Computed tomographic scans of the chest and abdomen revealed a solitary irregular mass (4.5 cm) in the apical segment of the left lung adhering to the thoracic inlet with no evidence of local recurrence in the abdomen.

Extrapleural resection of the tumour with the apical segment of the lung was performed. Histological examination proved the metastatic origin of the tumour from RCC. Nine months after resection of the metastatic tumour the patient had a relapse in the left thoracic inlet. Residual left upper lobectomy with excision of ribs 1-4 and the infiltrated part of the brachial plexus was performed. Seven months later the patient underwent radiation therapy to the tumour bed and supraclavicular region because of metastases in the scalene nodes (total dose 60 Gy in 27 fractions over 41 days).

Twenty five months after the first metastatic resection the patient's general condition deteriorated due to dissemination of the disease. Radiological examination showed

several new foci in both lungs and a metastatic tumour in the brain. The patient died 31 months after the first thoracotomy and 11 years after nephrectomy.

We conclude that metastatic RCC should be considered as a possible cause of Pancoast's syndrome. The resection should be as radical as in NSCLC—if necessary involving the adjacent structures—which should have been done in our first operation.

T W Marjanski, W Rzyman, J Skokowski
Thoracic Surgery Department, Medical University of Gdansk, Poland; wrzyman@amg.gda.pl

References

- 1 **Chang CF, Su WJ, Chou TY, et al.** Hepatocellular carcinoma with Pancoast's syndrome as an initial symptom: a case report. *Jpn J Clin Oncol* 2001;**31**:119-21.
- 2 **Goldman SM, Fajardo AA, Naraval RC, et al.** Metastatic transitional cell carcinoma from the bladder: radiographic manifestations. *AJR* 1979;**132**:419-25.
- 3 **Amin R.** Bilateral Pancoast's syndrome in a patient with carcinoma of the cervix. *Gynecol Oncol* 1986;**24**:126-8.

BOOK REVIEW

The Clinician's Guide to Asthma

Kian Fan Chung. London: Arnold. 165 pp. £29.99. ISBN 0 340 76287 X

This is an easy to read and thorough guide to asthma which covers a wide range of topics from prevalence to treatment, pharmacology to pathology. The text is engaging and interesting. It is well illustrated with numerous pictures and diagrams that enhance its readability. The strength of this book lies in

its clarity. Even the chapter on the pathophysiology of asthma can be read and understood by those who feel weak at the very mention of cytokines! It is also a contemporary text and provides a useful insight into emerging ideas and novel treatments in this field. The book is suited to those who wish to obtain a broad overview of the subject and would suit medical and MRCP students, respiratory trainees, and other health professionals involved in the care of the asthmatic patient.

Although the management of the asthmatic patient is covered in detail, this is not a handbook to guide individual patient care but is, instead, a concise and thoughtful review of the disease.

In summary, if asthma is not your primary field of interest and you were asked to give a talk on the subject tomorrow, you would be well advised to hunt out this book.

C M Richardson

Department of Respiratory Medicine, Glenfield Hospital, Groby Road, Leicester LE3 9QP, UK; catherine.richardson@tyne007.freeserve.co.uk

CORRECTION

Montelukast and inhaled budesonide in mild to moderate asthma

In the paper entitled "Effect of montelukast added to inhaled budesonide on control of mild to moderate asthma" by M J Vaquerizo *et al* which appeared in the March issue of *Thorax* (2003;**58**:204-11), there is an error in the first sentence of the abstract which should read "Proinflammatory leukotrienes, which are **not** completely inhibited by inhaled corticosteroids, may contribute to asthmatic problems". The publishers apologise for this error.