

Histologic and Electromyographic Evaluation of Neuroregenerative Effect of Stromal Vascular Fraction Following Neuroanastomosis ^[1]

Hilal ACAR ^{1,a} Ece ÇERÇİ ^{2,b} Marzieh Karimi KHEZRI ^{3,c} Melike ÇETİN ^{1,d} Uygur CANATAN ^{1,e}
Mehmet Metin ŞEN ^{1,f} Vildan ASLAN ^{1,g} Canan ALTINCI SARIL ^{1,h} Elif MEKİK TEMİZ ^{1,i}
Mevlüt Özgür TAŞKAPILIOĞLU ^{3,j} Hatice ERDOST ^{2,k} Hakan SALCI ^{1,l}

^[1] This study was performed by supporting of a scientific research project in Bursa Uludag University (Project no: BUAP(V)-2015/3)

¹ Department of Surgery, Faculty of Veterinary Medicine, Bursa Uludag University, TR-16059 Bursa - TURKEY

² Department of Histology and Embriology, Faculty of Veterinary Medicine, Bursa Uludag University, TR-16059 Bursa - TURKEY

³ Department Neurosurgery, Faculty of Medicine, Bursa Uludag University, TR-16059 Bursa - TURKEY

ORCIDs: ^a 0000-0003-0154-9938; ^b 0000-0002-2740-4262; ^c 0000-0002-6397-0966; ^d 0000-0001-5424-3321; ^e 0000-0001-9650-0891; ^f 0000-0001-5962-0202

^g 0000-0001-5323-6891; ^h 0000-0002-1418-3157; ⁱ 0000-0003-3407-4836; ^j 0000-0001-5472-9065; ^k 0000-0003-1547-7293; ^l 0000-0001-6548-8754

Article ID: KVFD-2019-23576 Received: 13.11.2019 Accepted: 23.03.2020 Published Online: 29.03.2020

How to Cite This Article

Acar H, Çerçi E, Khezri MK, Çetin M, Canatan C, Şen MM, Aslan V, Altinci Saril C, Mekik Temiz E, Taşkapılıoğlu MÖ, Erdost H, Salci H: Histologic and electromyographic evaluation of neuroregenerative effect of stromal vascular fraction following neuroanastomosis. *Kafkas Univ Vet Fak Derg*, 26 (4): 483-490, 2020. DOI: 10.9775/kvfd.2019.23576

Abstract

In this study, histologic and electromyographic (EMG) evaluation of neuroregenerative effect of stromal vascular fraction (SVF) following periferal nerve anastomosis was aimed. Totally, 31 Wistar Albino, male rats (weighing about 300 g) were studied, and these rats were grouped according to surgical techniques performed on the right sciatic nerve: group I (GRI) micro suture (n=7), group II (GRII) micro suture + SVF (n=7), group III (GRIII) fibrin glue (n=7) and group IV (GRIV) fibrin glue + SVF (n=7). Fat tissue was taken from 3 rats to prepare SVF, and SVF was produced by non-enzymatic method. The left sciatic nerve of all rats was evaluated for EMG as control. Under general anesthesia, after transversal incision of the sciatic nerve, microsurgical epineural repair technique was performed with 10/0 nonabsorbable suture. EMG examinations were performed in terms of conduction rate, amplitude, distal latency and spontaneous muscle activity at 0th day and postoperative (PO) ^{1st} and 8th weeks. EMG results between and within the groups were statistically evaluated by one-way analysis of variance. Rats in all groups were sacrificed by decapitation at PO 8th week and histological examinations of the sciatic nerves were performed following preparation of the neural tissues. EMG examination results showed the highest nerve conduction in GRI, the highest amplitude in GRIII, normal latency in GRII and longer distal latency in GRIV at PO 8th week. Amplitude and conduction velocity increased gradually in all groups. In needle EMG, the best muscle membrane stabilization was achieved in GRII and GRIV at PO 8th week. Statistically, the values of amplitude, distal latency, conduction velocity, and spontaneous muscle activity were found to be at normal levels at PO 8th week in all groups (P>0.05). In the histological results, although fibroconnective tissue reactions in the anastomosis area had similar scores in GRII and GRIV, maximum fibroconnective tissue reaction and the best axonal regeneration was seen in GRI and GRIII, respectively. In addition, GRI and GRII had the most inflammatory cells accumulation in the suture region, and less inflammatory cells were seen in the anastomosis area of GRIII and GRIV. As a conclusion, fibrin glue presents good electrophysiological and histological results; however, it is clear that local SVF usage on the nerve anastomosis area can be a good choice to decrease fibroconnective tissue reaction and inflammation.

Keywords: Electromyography, Histology, Neuroanastomosis, Rat, Stromal vascular fraction

Nöroanastomoz Sonrası Stromal Vasküler Fraksiyonun Nörorejeneratif Etkisinin Histolojik ve Elektromiyografik Değerlendirilmesi

Öz

Bu çalışmada, periferal sinir anastomozunu takiben stromal vasküler fraksiyonun (SVF) nörorejeneratif etkisinin histolojik ve elektromiyografik (EMG) değerlendirilmesi amaçlandı. Toplamda, 31 Wistar Albino, erkek sıçanda (yaklaşık 300 gr ağırlığında) çalışıldı ve bu sıçanlar sağ siyatik sinirde uygulanan cerrahi tekniklere göre gruplandı: grup I (GRI) mikro dikiş (n=7), grup II (grup GRII) mikro dikiş + SVF (n=7), grup III (GRIII) fibrin yapıştırıcı (n=7) ve grup IV (GRIV) fibrin yapıştırıcı + SVF (n=7). SVF'yi hazırlamak için 3 sıçandan yağ dokusu alındı ve SVF, enzimatik olmayan bir yöntemle üretildi. Bütün sıçanların sol siyatik siniri EMG için kontrol olarak değerlendirildi. Genel anestezi altında, siyatik sinirin transversal ensizyonundan sonra 10/0 emilemeyen dikiş ile mikrocerrahi epinöral onarım tekniği uygulandı. EMG muayeneleri, 0. günde ve postoperatif (PO) 1. ve 8. haftalarda iletim hızı, amplitüd, distal latans ve spontan kas aktivitesi açısından yapıldı. EMG bulguları istatistiksel olarak gruplar arası ve grup içi tek yönlü varyans analizi ile değerlendirildi. Tüm gruplardaki sıçanlar PO 8. haftada dekapitasyon ile sakrifiye edildi ve sinir dokularının hazırlanmasından sonra siyatik sinirlerin histolojik incelemeleri yapıldı. EMG muayene sonuçları, GRI'de en yüksek sinir iletimini, GRIII'te en yüksek amplitüdü, GRII'de normal latansı ve GRIV'te ameliyat sonrası 8. haftada daha uzun distal latansı gösterdi. Amplitüd ve iletim hızı, tüm gruplarda kademeli olarak arttı. İğne EMG'de, en iyi kas zarı stabilizasyonu PO 8. haftada GRII ve GRIV'te sağlandı. İstatistiksel olarak amplitüd, distal latans, ileti hızı ve spontan kas aktivitesi değerlerinin tüm gruplarda anlamlı olarak PO 8. haftada normal değerlerde olduğu görüldü (P>0.05). Histolojik sonuçlarda, anastomoz alanındaki fibrokonektif doku reaksiyonları GRII ve GRIV'te benzer skorlara sahip olsa da, maksimum fibrokonektif doku reaksiyonu ve en iyi aksonal rejenerasyon sırasıyla GRI ve GRIII'te görülmüştür. Ek olarak, GRI ve GRII dikiş bölgesinde en fazla enflamatuvar hücre birikimine sahipti ve GRIII ve GRIV'ün anastomoz alanında daha az enflamatuvar hücreler görüldü. Sonuç olarak, fibrin yapıştırıcısı iyi elektrofizyolojik ve histolojik sonuç sunar; ayrıca sinir anastomoz bölgesinde lokal SVF kullanımı fibrokonektif doku reaksiyonu ve enflamasyonu azaltmak için iyi bir seçim olabileceği açıktır.

Anahtar sözcükler: Elektromiyografi, Histoloji, Nöroanastomoz, Sıçan, Stromal vasküler fraksiyon



Correspondence



+90 224 2940841



hsalci@uludag.edu.tr

INTRODUCTION

Peripheral nerve regeneration after surgical repair of nerve tissue is a complex process that continues as molecular healing. Neurorrhaphy, tissue adhesives, and grafting are the routine techniques of nerve anastomosis^[1,2]. Neurorrhaphy is the most common choice, especially in situations where tension-free nerve endings are attached^[1-7]. Fibrosis, adhesion neuroma and glioma formation after neurorrhaphy has a negative effect on nerve healing^[1,4,5]. Because of the negative effects of neurorrhaphy on healing, tissue adhesives have been developed as an alternative^[1,2,8] and fibrin glue, which is used for neural anastomosis, reduces local inflammation and fibrosis and provides neurotropic factors^[2,6,9-11]. However, fibrin glue has been shown to inhibit local axonal regeneration by increasing local scar tissue formation and thus its usage has been limited^[6,9].

In recent years, cell-based therapy techniques have been applied in the field of regenerative medicine. Stromal vascular fraction (SVF) obtained from adipose tissue is also among these treatment techniques^[12-15]. SVF is a rich cellular source containing preadipocytes, mesenchymal stem cells, endothelial progenitor cells and adipose tissue-derived macrophages^[5,12,14,16-18]. SVF, composed of heterogeneous cell groups, contributes to nerve regeneration with its angiogenic and immunosuppressive effects^[17,19]. Therefore, SVF has many indications such as lipotransfer, cardiac diseases, diabetes-related complications, nerve regeneration and burn wounds^[12,14,16,17]. In addition, SVF is used as uncultured adipose-derived stromal cells and has advantages such as rapid derivation and reduction in transplantation, economize and reducing the risk of cell culture^[5,13,20-23].

On the basis of the literature information given above, using histological and electromyographic (EMG) examinations, this presented study aimed to investigate the neuro-regenerative effect of locally applied SVF in neuro-anastomosis following suture and fibrin glue after sciatic nerve transection.

MATERIAL and METHODS

Animals and Grouping

This study was approved by Bursa Uludag University Animal Experiments Local Ethics Committee (Decision no: 2019-03/07).

The materials of the study consisted of 31 adult (n=31) Wistar Albino male rats weighing approximately 300 grams. All rats were allowed to illuminate for 12 h daytime and 12 h nighttime with an average temperature of 22°C, and the rats were fed *ad libitum*. Rats were randomly selected for the study groups. The study was performed on the right sciatic nerve: group I (GRI) micro suture (n=7), group II (GRII) micro suture + SVF (n=7), group III (GRIII) fibrin glue (n=7) and group IV (GRIV) fibrin glue + SVF

(n=7). Fat tissue was taken from 3 rats to prepare SVF. The sciatic nerve of the left extremity of all rats was evaluated for EMG examination as control.

Experimental Procedure

The microsurgical procedure was performed under general anesthesia in accordance with the rules of asepsis and antisepsis. Xylazine HCl (9 mg/kg, IM) (Alfazine®, Egevet, Turkey) was used as preanesthetic and ketamine HCl (50 mg/kg, IM) (Alfamine®, Egevet, Turkey) was administered for induction. The sciatic nerve on the right extremity of the rats was reached by lateral approach. Transversal incision was made with scalpel one cm proximal to the bifurcation of the nerve. The surgical loop was used during the operation for magnification, so that the micro-imaging and nerve endings were confronted. In GRI and GRII, four micro sutures were applied by epineural repair technique using 10/0 non-absorbable suture material (Ethicon®, USA) (Fig. 1-A). After the suturing procedure in GRII, the SVF prepared before the surgical procedure was absorbed into the surgical (Ethicon®, USA) and delivered to anastomosis area locally (Fig. 1-B). After transection in GRIII and GRIV, nerve endings were adhered with 4 mL fibrin glue (Tisseel®, Baxter, Austria) (Fig. 1-C). After adhesion of nerve endings in GRIV, SVF impregnated with surgical (Ethicon®, USA) was applied locally (Fig. 1-D). After the procedures applied to the nerves in all groups, the surgical site was routinely closed.

In the postoperative (PO) period, meloxicam (1 mg/kg, IM) was used once daily for three days and enrofloxacin (10 mg/kg, IM, qd) was used for a week to all rats. All groups were sacrificed by decapitation at PO 8th weeks.

EMG Procedure

To assess functional nerve healing, EMG examination was performed at 0th day and PO 1st and 8th weeks using Medtronic Dantec Keypoint 4 EMG (Bourgogne, France). For the motor conduction velocity examination of the sciatic nerve, supra-maximal stimulation was given by monopolar needle electrodes from the back of genu and acetabulum. The ground electrode was placed between stimulator and recording electrode. The compound muscle action potential (CMAP) was recorded from gastrocnemius muscle. Distal latency, amplitude and nerve conduction velocity were evaluated. In needle EMG, tibialis cranialis muscle and gastrocnemius muscle, at 0.2 mV and 10 ms/D, spontaneous muscle activity was examined with concentric needle electrodes. Spontaneous activity of the muscles examined as reported previously^[24]; +1: sparse fibrillation potentials or positive sharp waves, +2: fibrillation potentials or positive sharp waves in multiple sites in a muscle, +3: abundant spontaneous activity, +4: significant fibrillation potentials or positive sharp waves to fill the screen.

Collection of Adipose Tissue and SVF Preparation Protocol

For SVF preparation, the fat tissue was taken of the inguinal

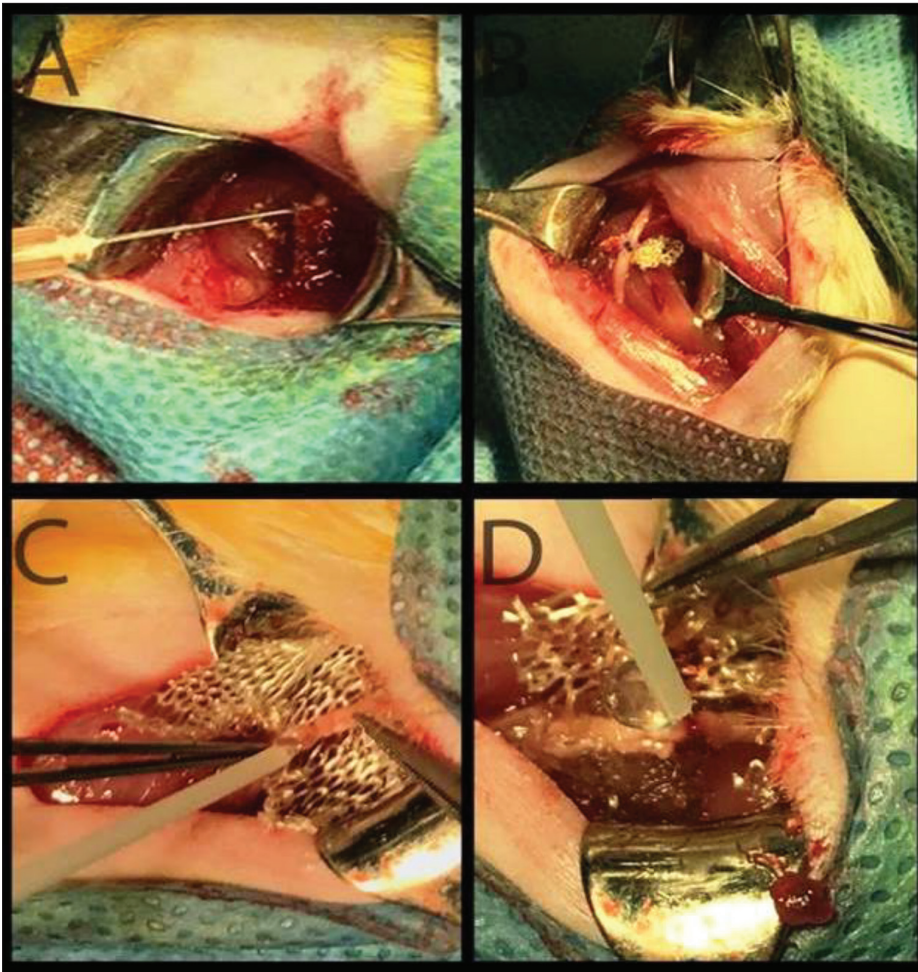


Fig 1. Intraoperative view of the procedures applied in GRI (A), GR II (B), GR III (C) and GR IV (D)

region under general anesthesia from three rats. In total, 2.898 g of clean adipose tissue was harvested from the animals. Non-enzymatic SVF method (mechanic) was performed as described previously^[25]. The adipose tissue was cut into small pieces then sterilized with alcohol for 2 sec in 50 mL falcon tube. Subsequent adipose tissues were washed with Dulbecco's phosphate buffered saline (D-PBS) separately performed in sterile petri dish. Adipose tissue samples was removed from D-PBS, placed into the 100 mm² petri dish and cut into the more small pieces (1-2 mm²) for mincing process^[26]. After this mincing process, 1.5 g of fat tissue + 1.5 mL of 0.08% isotonic content were added to 2 centrifuge tubes (15 mL volume). The centrifugation was carried out at 3500 rpm, 4°C for 4 min. After the supernatant was discarded, the pellet was filtered with 70-micron filter to use SVF. The 100 µL volume of fresh SVF was injected by insulin syringes into nerve anastomosis area of the rats.

Histological Procedure

After decapitation, nerve was quickly collected; soft tissues were removed from the nerve surfaces, and cut into small pieces. Specimens were fixed in 10% neutral buffered formalin for 3 days. When the fixation was completed, specimens were rinsed in water briefly. After dehydration

in 70% ethanol, 80% ethanol, 96% ethanol, and absolute ethanol, specimens were embedded in paraffin wax and than 6-7 µm thickness tissue sections were cut and stained with Crossman's triple staining method^[27]. Histology sections were examined microscopically (Nikon® Eclipse 80i Microscope, Netherlands). Photographs were taken with a camera (Nikon® Ds Camera Control Unit DS-L1, Japan).

The nerve regeneration was evaluated by nerve fiber alignment and fibrous tissue reaction in each section. To evaluate the axonal regeneration, fiber alignment of nerve was scored semiquantitatively: (+) weak, (++) moderate, (+++) strong, (+++++) very strong. The fibrous tissue reaction in the lesion area, all slides were scored as no collagen and/or connective tissue (-), weak (+), moderate (++) and strong (+++) by two researchers in a blind manner. The analysis was performed as reported previously^[28].

Statistical Evaluation

Statistical analyzes were done in SigmaStat verison 12.5 program (GmbH®, Germany). One-way analysis of variance (ANOVA) repeated measures test was used to compare electromyographic findings within and between groups. The results were evaluated at P<0.05 significance level.

RESULTS

The operation wound of all rats recovered without any complications and all rats survived until the end of the study. Nerve transection revealed right posterior limb paralysis in all rats which was evident in PO 1st week.

EMG Results

In GRI; conduction velocity was 31.6±1.6 m/s at PO 1st week and 71±5.8 m/s at PO 8th weeks. Amplitude was 0.6±0.5 mV at PO 1st week and 5.7±1.4 mV at PO 8th weeks; the distal latency was 4.95±0.05 ms at PO 1st week and 1.4±0.2 ms at PO 8th week. The amplitude, distal latency and conduction velocity were found to be increased when the values of PO 1st and 8th week were compared. Compared with the left extremity for control, conduction velocity was close to normal values at PO 8th weeks, but amplitude was lower than normal value and distal latency was longer. In needle EMG, severe fibrillation and positive sharp waves were observed in PO 1st week, denervation potentials became stable in PO 8th week.

In GRII, conduction velocity was 37.1±7.4 m/s in PO 1st week and 53±7.9 m/s in PO 8th week. The amplitude was 3±1.5 mV at PO 1st week and 4.1±0.7 mV at PO 8th week;

distal latency was 1.7±0.6 ms at PO 1st week and 1.1±0.1 ms at PO 8th week. When compared with control, conduction rate and amplitude were significantly lower than normal value and distal latency was longer than normal. In needle EMG, severe fibrillation and positive sharp waves were observed in the PO 1st week, denervation potential was stable in many rats individually at PO 8th weeks.

In GRIII; conduction velocity was 59.2±7.5 m/s in PO 1st week and 68.3±3.1 m/s in PO 8th week. Amplitude was 1±0.5 mV at PO 1st week and 6.6±1.5 mV at PO 8th weeks; the distal latency was 1.3±0 ms at PO 1st week and 1.4±0.4 ms at PO 8th week. When compared to left extremity as control, conduction velocity was found to be close to normal value. Severe spontaneous activity was observed in needle EMG at PO 1st week. Fibrillation and positive sharp wave potentials decreased to the minimum and muscle membrane was stable at PO 8th weeks.

In GRIV; the rate of conduction was 39.1±8.2 m/s at PO 1st week and 52.7±9.3 m/s at PO 8th weeks. The amplitude was 1.4±0.3 mV at PO 1st week and 3.4±0.8 mV at PO 8th weeks; the distal latency was 1.6±0.4 ms in PO 1st week and 2.5±1.6 ms in PO 8th week. When compared to left extremity as control, conduction velocity and amplitude were lower than normal value and distal latency was longer than

normal. Severe spontaneous activity was observed in needle EMG at PO 1st week. It was observed that fibrillation and positive sharp wave potentials minimized and membrane stability was not achieved in many rats at PO 8th week.

Graphical changes in amplitude and conduction velocities of all groups at 0th day and PO 1st and 8th weeks were shown in Fig. 2.

Histological Results

Macroscopically, color change and thinning of the anastomosis area was observed in all groups. In GRI and GRII, suture materials were observed in the anastomosis area. Longitudinal continuity in the sciatic nerve was seen in all rats of all groups. Separation of the distal and proximal nerve segments and adherence of the segments to muscle tissues were not observed. During the study, ototomy was observed in one rat in GRII and four rats in GRIII.

Histological assessments are given in Table 1.

Regeneration of Ischiadic Nerve: Axonal regeneration and fiber alignment were found to be better in GRIII compared

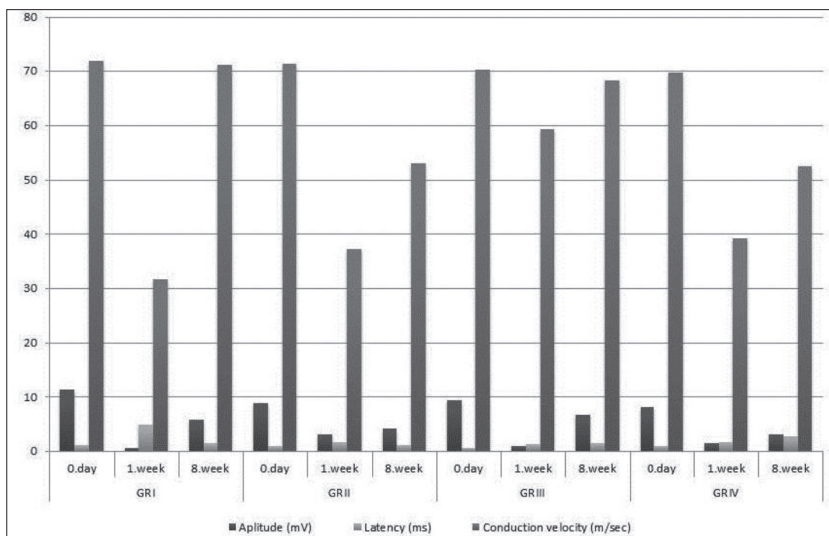


Fig 2. EMG examination results of all groups

Table 1. Score results of axonal regeneration of sciatic nerve

Parameter of Histologic Evaluation	GRI	GRII	GRIII	GRIV
Fiber alignment	++	+	+++	++
Fibrous tissue reaction (anastomosis area)	+++	++	+	++

Fiber alignment: (+) weak, (++) moderate, (+++) strong, (++++) very strong; **Fibrous connective tissue reaction:** (-) no collagen; (+) collagen and/or connective tissue between fibers; (++) connective tissue that partially interrupts fiber passage; (+++) connective tissue that totally interrupts fiber passage

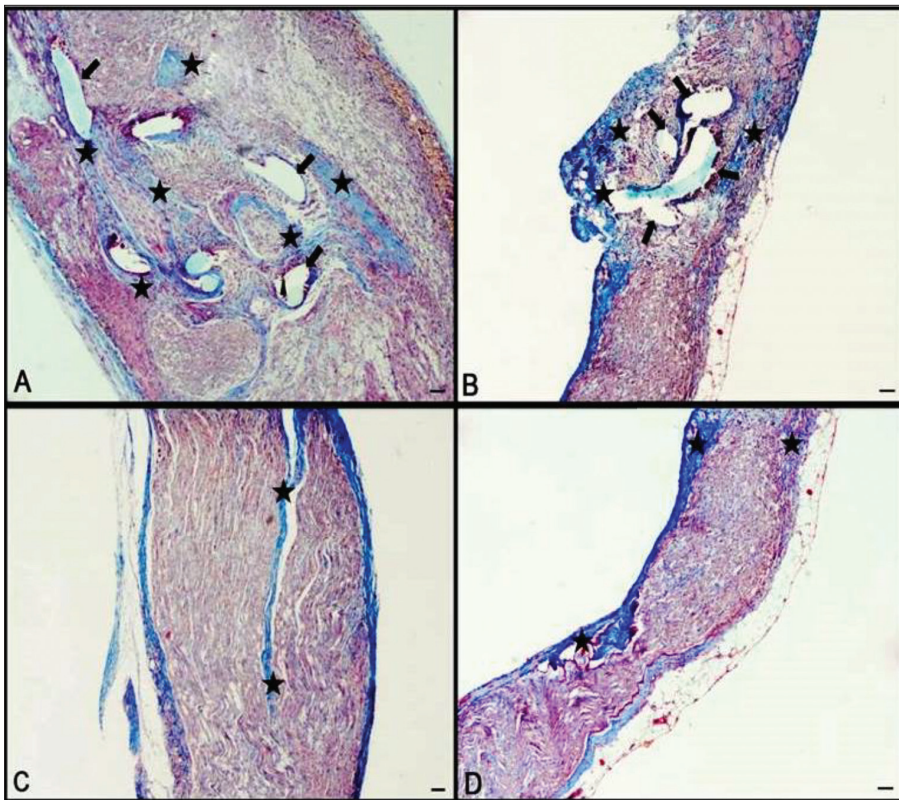


Fig 3. Longitudinal histologic section of GRI (A), GRII (B), GRIII (C) and GRVI (D): experimental groups. Fibroconnective tissue reactions (*); decrease of fiber alignment and interruption-suture area (arrows); Triple stain, Bar 100 μ m

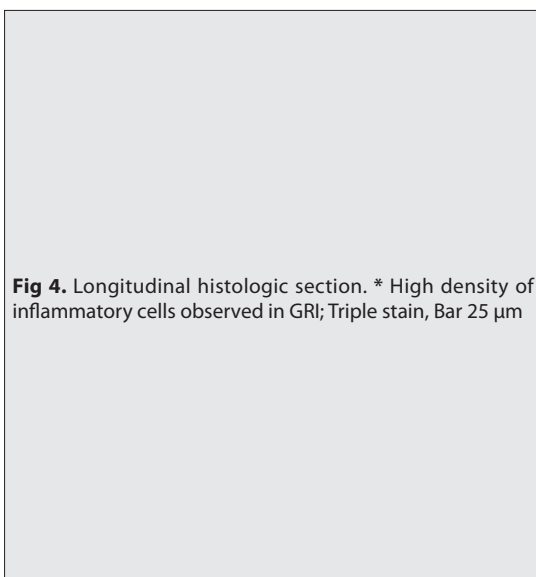
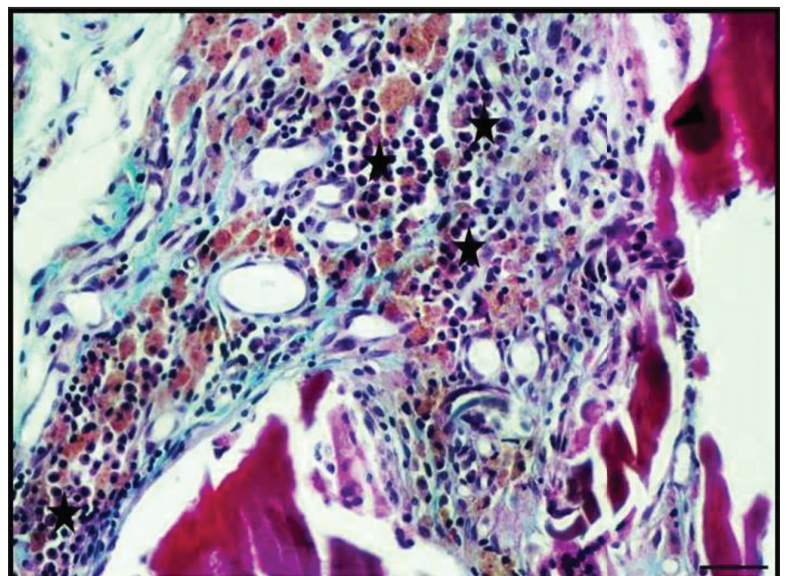


Fig 4. Longitudinal histologic section. * High density of inflammatory cells observed in GRI; Triple stain, Bar 25 μ m



to the other groups (Table 1, Fig. 3-C). In GRIII, less fibroconnective tissue reactions were determined (Fig. 3-C), and maximum fibroconnective tissue reactions were observed in GRI (Fig. 3-A). Fibroconnective tissue reactions in the anastomosis area had similar scores (++) in GRII (Table 1, Fig. 3-B) and GRIV (Table 1, Fig. 3-D). A significant decrease in fiber alignment was observed due to increased density of fibrous connective tissue reaction (Fig. 3-A). Furthermore, it was found that the fiber alignment was partially and completely interrupted in GRI (Fig. 3-A). There was a considerable connective tissue reaction in

the perineural area of all groups compared with the controls. When the inflammation of the nerve fibers was examined, it was seen that GRI and GRII had the most inflammatory cells in the sutured area (Fig. 4), and less inflammatory cells were observed in GRIII and GRIV (Fig. 3-C,D).

Statistical Results

The statistical comparisons of amplitude, distal latency, conduction velocity, and needle EMG results are detailed in Table 2 and Table 3.

Table 2. This table points out the nerve conduction study values of the groups

Group	Amplitude (mV) Mean±SE			Distal Latency (ms) Mean±SE			Conduction Velocity (m/s) Mean±SE		
	0. day	1. week	8. week	0. day	1. week	8. week	0. day	1. week	8. week
GRI	11.3±1.6 ^{aA}	0.6±0.5 ^{b**A}	5.7±1.4 ^{abA}	1.0±0.3 ^{aA}	4.9±0.0 ^{b**A}	1.4±0.2 ^{aA}	71.8±5.1 ^{aA}	31.6±1.6 ^{b**A}	71±5.8 ^{aA}
GRII	8.5±2.1 ^{aA}	3±1.5 ^{b*A}	4.1±0.7 ^{abA}	0.8±0.1 ^{aA}	1.7±0.6 ^{b**B**}	1.1±0.1 ^{b*A}	70.5±2.6 ^{aA}	37.1±7.4 ^{b**A}	53±7.9 ^{abA}
GRIII	9.3±2.6 ^{aA}	1±0.5 ^{aA}	6.6±1.5 ^{aA}	0.5±0 ^{aA}	1.3±0.0 ^{b*B**}	1.4±0.4 ^{abA}	70.3±9.7 ^{aA}	59.2±7.5 ^{aA}	68.3±3.1 ^{aA}
GIV	7.7±1.6 ^{aA}	1.4±0.3 ^{b**A}	3.4±0.8 ^{b**A}	0.8±0.1 ^{aA}	1.6±0.4 ^{B**}	2.5±1.6 ^{aA}	69±3.6 ^{aA}	39.1±8.2 ^{b**A}	52.7±9.3 ^{aA}

* P<0.05, ** P<0.01 and *** P<0.001; **Within groups:** Same letters (a, b and c) in the same line are not statistically significant (P>0.05); **Between groups:** Same letters (A and B) in the same column are not statistically significant (P>0.05)

Table 3. The mean and standart errors (SE) and also statistical analysis results of the needle EMG values in groups

Group	Tibialis cranialis muscle Mean±SE			Gastrocnemius muscle Mean±SE		
	0. day	1. week	8. week	0. day	1. week	8. week
GRI	0±0 ^{aA}	4±0 ^{b***A}	2±0 ^{c***A}	0±0 ^{aA}	4±0 ^{b***A}	1±0 ^{b***A}
GRII	0±0 ^{aA}	3±0.3 ^{b***A}	0.6±0.3 ^{abA}	0±0 ^{aA}	3±0.2 ^{b***B*}	0.8±0.3 ^{c***A}
GRIII	0±0 ^{aA}	3±1 ^{b*A}	0.5±0.5 ^{abA}	0±0 ^{aA}	3±0 ^{b**B*}	0±0 ^{aA}
GRIV	0±0 ^{aA}	2.4±0.3 ^{b***A}	1±0.2 ^{c***A}	0±0 ^{aA}	3±0 ^{b***B*}	0.8±0.1 ^{c***A}

* P<0.05, ** P<0.01 and *** P<0.001; **Within groups:** Same letters (a, b and c) in the same line are not statistically significant (P>0.05); **Between groups:** Same letters (A and B) in the same column are not statistically significant (P>0.05)

In the Evaluation of Nerve Conduction Velocity

Amplitude Values: The decrease in the amplitude values of GRI and GRIV at PO 1st week was significant within the group comparison (P<0.05), it was close to normal values in GRI, GRII, GRIII at PO 8th week but there was no statistical significance (P>0.05). In the GRIV, the PO 8th week, amplitude value was not close to values of day 0 (P<0.05). There was no significant difference in the 8th week amplitude values between the groups (P>0.05).

Distal Latency: In the groups comparison, a significant difference was found between values of day 0 and PO 1st week of GRI, GRII and GRIII (P<0.01). In the PO week 1, GRI had a significant difference between the other groups (P<0.01), and there was no significant difference between the groups at PO week 8 (P>0.05).

Conduction Velocity: There was a significant difference in the comparison of GRI, GRII and GRIV within the group (P<0.01). In the comparison between the groups, no significant difference was determined between the PO 8th week values (P>0.05).

In the Evaluation of the Needle EMG

The increase in spontaneous activity of tibialis cranialis and gastrocnemius muscles at PO 1st week was found to be significant within grup evaluations of all groups (P<0.001). At PO 8th week, decrease in spontaneous activity of tibialis cranialis muscle was significant in GRI, GRII and GRV (P<0.001). While spontaneous muscle activity of

gastrocnemius was significant only in the GRI at PO week 1 (P<0.001), it was statistically significant among all groups at PO 8 week (P>0.05).

DISCUSSION

In peripheral nerves, morphological and cellular changes occur in the nerve fragments as a result of partial or total damage [7,11]. The success of peripheral nerve repair depends on the density of regenerated axons and prominent regenerating myelin at the junction along with regenerating axons [11,29]. From past to present, many methods have been used to achieve optimal functional recovery in nerve regeneration [10,30]. Among these methods, micro suture technique is frequently preferred [3,5,8,31]. Epineural and perineural techniques provide better contact between nerve segments in nerve repair and cause nerve fibers to deteriorate and become more traumatized [8,9,11,31,32]. However, fibrin glue is an atraumatic technique that does not have foreign body effects on the nerve [31,32] and also reduces inflammation and fibrosis [8,10,32]. Fibers in fibrin glue-repaired nerves generally extend parallel to the axis, whereas suture-repaired nerves are known to interfere with axonal growth during regeneration [9,10,32]. In addition, suturing can prevent blood circulation by compressing the fascicles [11,32].

Thus, there is still a controversial statement, which surgical technique is ideal for peripheral nerve repair [10,31]. In this presented study, neuroanastomosis was performed in the

sciatic nerve using epineural micro suture and fibrin glue repair techniques. And the local effect of SVF on nerve regeneration, following to nerve repairment, was investigated by PO EMG examinations and nerve histology study, which was determined as 8 weeks based on axonal re-growth and functional regeneration time, as reported previously [33,34].

In comparative studies with fibrin glue and epineural repair, there is no detail in which the superiority was reported with histological findings [11,32]. It has been reported that fibrin glue may cause compression of the nerve by causing connective tissue reaction [11]. However, Breshah et al. [2] and Rafijah et al. [6], have been reported that fibrin glue has no negative effect on nerve regeneration and may even be functionally alternative to epineural suture repair. In addition, fibrin glue applied for neural anastomosis has better functional return and has superiority electrophysiologically [35,36]. In this study, there was a reduction in the continuity of the axons in group applied only micro suture. Moreover, comparing to the suturing groups (GRI and II), fibrin glue (GRIII) presented better electrophysiological results, and minimal inflammatory reaction and fibrosis on the anastomosis site of the nerve in histological evaluation.

The effect of SVF on nerve regeneration is not fully understood, but stromal, multipotent and hematopoietic cell populations are known to contribute to regeneration. It is also reported that regenerated axons heal faster and myelinated fibers have larger diameters [17]. Local neuroprotective effect of SVF was reported in diabetic rats [9]. In a nerve graft study, regeneration is better in SVF filled vein grafts and these grafts can be used in peripheral nerve regeneration instead of autologous nerve graft [15]. Mohammadi et al. [22] has been reported that SVF has favorable effects on nerve regeneration histologically. In SVF groups (GRII and GRIV) of this study, the inflammation was significantly minimal. Furthermore, SVF showed less fibroconnective tissue reaction compared to the group where only micro suture was applied, and it was considered as an important result of reducing the fibrous tissue reaction of SVF.

Electromyographic examination provides important information for the determination of axonal regeneration and functional recovery after surgical repair of peripheral nerves [37]. In addition, Sta et al. [38], has been stated that the electrophysiologic evaluation is very sensitive in early stage nerve regeneration. Amplitudes, an indicator of regenerated axon count [7,9,19,32], increased gradually in all groups at PO 8th weeks. As informed by Martins et al. [39], the highest amplitude was determined in fibrin glue group (GRIII) at PO 8th week. The absence of statistical significance in amplitude values of GRIII during the study was interpreted that fibrin glue had a positive effect on nerve regeneration. CMAP latencies are also indicative of nerve conduction velocity and correlate with the level of axonal

myelination and nerve regeneration. Low distal latency is revealing of higher conduction velocity and recovery [9]. Comparing to the and 8th week distal latency values of the groups, there was the longest distal latency in micro suture group at PO 1st week, which could be indicative for demyelination; however, the closest distal latency value was determined in micro suture plus SVF group (GRII) at PO 8th week. In the comparison between the groups, the message speed reached normal values in the 8th week EMG examination of all groups and there was no statistically significant difference between them ($P>0.05$).

Needle EMG is performed in the target organ muscles in order to evaluate reinnervation [7]. Electrophysiological methods have been reported to be the best indicator of nerve healing in the period from nerve repair to muscle re-innervation [28]. In addition, the fibrillation potentials used in clinical routine and the numerical evaluation scale of positive sharp waves ranging from +1 to +4 provide semi-measurable results about denervation in muscles [24]. In needle EMG, there was serious denervation potential in all groups at PO 1st week, but this activity decreased until the end of the study period, but the muscles were not completely stable. In the evaluation of spontaneous muscle activity, it was determined that gastrocnemius muscle activity was higher in the GRI at PO 1st week compared to the other groups ($P<0.001$), but there was no significant difference between the groups at the PO 8th week ($P>0.001$). The best recovery was the fibrin glue group as a result of semi-quantitative evaluation in parallel with histological findings. Muscle membrane stabilization was faster in SVF groups in the evaluation of re-innervation. Also, the fact that the potential for denervation in the groups using SVF started to decrease earlier may mean that SVF can contribute to reinnervation.

In conclusion, considering the presented study data, fibrin glue offers the best electrophysiological and histological results; SVF has been shown to reduce fibroconnective tissue reaction and inflammation, and may contribute to reinnervation by creating electrophysiological early denervation potential. Therefore, it is clear that SVF can be a potential alternative to the use of stem cells and growth factors.

REFERENCES

1. Barton MJ, Morley JW, Stoodley MA, Lauto A, Mahns DA: Nerve repair: Toward a sutureless approach. *Neurosurg Rev*, 37 (4): 585-595, 2014. DOI: 10.1007/s10143-014-0559-1
2. Breshah MN, Sadakah AA, Eldrieny EA, Saad KA: Functional and histological evaluation of rat sciatic nerve anastomosis using cyanoacrylate and fibrin glue. *Tanta Dent J*, 10 (2): 67-74, 2013. DOI: 10.1016/j.tdj.2013.08.005
3. Flores AJ, Lavernia CJ, Owens PW: Anatomy and physiology of peripheral nerve injury and repair. *Am J Orthop (Belle Mead NJ)*, 29 (3): 167-173, 2000.
4. Özyayın İ, Ünsaldı E, Aksoy Ö, Yayla S, Kaya M, Ulkay Tunalı MB, Aktaş A, Taşdemiroğlu E, Cihan M, Kurt B, Yıldırım HC, Şengöz A, Erdoğan H: The effect of silicone tube and silicone tube + hyaluronic

- acid application on adhesion formation in experimental peri- and epineurolysis in a rat model. *Kafkas Univ Vet Fak Derg*, 20 (4): 591-597, 2014. DOI: 10.9775/kvfd.2014.10583
- 5. Panagopoulos GN, Megalioikonomos PD, Mavrogenis AF:** The present and future for peripheral nerve regeneration. *Orthopedics*, 40 (1): e141-e156, 2017. DOI: 10.3928/01477447-20161019-01
- 6. Rafijah G, Bowen AJ, Dolores C, Vitali R, Mozaffar T, Gupta R:** The effect of adjuvant fibrin sealant on the surgical repair of segmental nerve defects in an animal model. *J Hand Surg*, 38 (5): 847-855, 2013. DOI: 10.1016/j.jhsa.2013.01.044
- 7. Wood MD, Kemp SWP, Weber C, Borschel GH, Gordon T:** Outcome measures of peripheral nerve regeneration. *Ann Anat*, 193 (4): 321-333, 2011. DOI: 10.1016/j.aanat.2011.04.008
- 8. Bhandari PS:** Use of fibrin glue in the repair of brachial plexus and peripheral nerve injuries. *Indian J Neurotrauma*, 10 (1): 30-32, 2013. DOI: 10.1016/j.ijnt.2013.05.008
- 9. Bhatnagar D, Bushman JS, Murthy NS, Merolli A, Kaplan HM, Kohn J:** Fibrin glue as a stabilization strategy in peripheral nerve repair when using porous nerve guidance conduits. *J Mater Sci Mater Med*, 28:79, 2017. DOI: 10.1007/s10856-017-5889-4
- 10. Childe JR, Regal S, Schimoler P, Kharlamov A, Miller MC, Tang P:** Fibrin glue increases the tensile strength of conduit-assisted primary digital nerve repair. *Hand*, 13 (1): 45-49, 2018. DOI: 10.1177/1558944717691131
- 11. Suri A, Mehta VS, Sarkar C:** Microneural anastomosis with fibrin glue: an experimental study. *Neurol India*, 50 (1): 23-26, 2002.
- 12. Aksu AE, Çaliş M:** Yağ dokusundan elde edilen mezenkimal kök hücreler ve stromal vasküler fraksiyon konsepti. *Türkiye Klinikleri J Plast Surg- Special Topics*, 4 (3): 19-26, 2015.
- 13. Matsumine H, Numakura K, Klimov M, Watanabe Y, Giatsidis G, Orgill DP:** Facial-nerve regeneration ability of a hybrid artificial nerve conduit containing uncultured adipose-derived stromal vascular fraction: An experimental study. *Microsurgery*, 37 (7): 808-818, 2017. DOI: 10.1002/micr.30060
- 14. Nguyen A, Guo J, Banyard DA, Fadavi D, Toranto JD, Wirth GA, Paydar KZ, Evans GRD, Widgerow AD:** Stromal vascular fraction: A regenerative reality? Part 1: Current concepts and review of literature. *J Plast Reconstr Aesthet Surg*, 69 (2): 170-179, 2016. DOI: 10.1016/j.bjps.2015.10.015
- 15. Özkan HS, Silistreli ÖK, Ergür B, İrkören S:** Repairing peripheral nerve defects by vein grafts filled with adipose tissue derived stromal vascular fraction: An experimental study in rats. *Ulus Travma Acil Cerrahi Derg*, 22 (1): 7-11, 2016. DOI: 10.5505/tjtes.2015.12612
- 16. Gentile P, Scioli MG, Bielli A, Orlandi A, Cervelli V:** Concise review: The use of adipose-derived stromal vascular fraction cells and platelet rich plasma in regenerative plastic surgery. *Stem Cells*, 35 (1): 117-134, 2017. DOI: 10.1002/stem.2498
- 17. Guo J, Nguyen A, Banyard DA, Fadavi D, Toranto JD, Wirth GA, Paydar KZ, Evans GRD, Widgerow AD:** Stromal vascular fraction: A regenerative reality? Part 2: Mechanisms of regenerative action. *J Plast Reconstr Aesthet Surg*, 69 (2): 180-188, 2016. DOI: 10.1016/j.bjps.2015.10.014
- 18. Mohammadi R, Sanaei N, Ahsan S, Rostami H, Abbasipour-Dalivand S, Amini K:** Repair of nerve defect with chitosan graft supplemented by uncultured characterized stromal vascular fraction in streptozotocin induced diabetic rats. *Int J Surg*, 12 (1): 33-40, 2014. DOI: 10.1016/j.ijssu.2013.10.018
- 19. Shimizu M, Matsumine H, Osaki H, Ueta Y, Tsunoda S, Kamei W, Hashimoto K, Niimi Y, Watanabe Y, Miyata M, Sakurai H:** Adipose-derived stem cells and the stromal vascular fraction in polyglycolic acid-collagen nerve conduits promote rat facial nerve regeneration. *Wound Repair Regen*, 26 (6): 446-455, 2018. DOI: 10.1111/wrr.12665
- 20. Bora P, Majumdar AS:** Adipose tissue-derived stromal vascular fraction in regenerative medicine: A brief review on biology and translation. *Stem Cell Res Ther*, 8:145, 2017. DOI: 10.1186/s13287-017-0598-y
- 21. Harasymiak-Krzyzanowska I, Niedojadlo A, Karwat J, Kotuła L, Gil-Kulik P, Sawiuk M, Kocki J:** Adipose tissue-derived stem cells show considerable promise for regenerative medicine applications. *Cell Mol Biol Lett*, 18, 479-493, 2013. DOI: 10.2478/s11658-013-0101-4
- 22. Mohammadi R, Azizi S, Delirez N, Hobbenaghi R, Amini K:** Transplantation of uncultured omental adipose-derived stromal vascular fraction improves sciatic nerve regeneration and functional recovery through inside-out vein graft in rats. *J Trauma Acute Care Surg*, 72 (2): 390-396, 2012. DOI: 10.1097/ta.0b013e31821181dd
- 23. Mohammadi R, Mehrtash M, Mehrtash M, Sajjadi SS:** Nonexpanded adipose stromal vascular fraction local therapy on peripheral nerve regeneration using allografts. *J Invest Surg*, 29 (3): 149-156, 2016. DOI: 10.3109/08941939.2015.1093046
- 24. Öge AE, Matur Z:** Sinir İletim Çalışmaları ve Elektromiyografi Atlası. 20-25, Nobel Yayınevi, İstanbul, 2013.
- 25. Shah FS, Wu X, Dietrich M, Rood J, Gimble JM:** A non-enzymatic method for isolating human adipose tissue-derived stromal stem cells. *Cytotherapy*, 15 (8): 979-985, 2013. DOI: 10.1016/j.jcyt.2013.04.001
- 26. Li YS, Chen PJ, Wu LW, Chou PW, Sun LY, Chiou TW:** Investigating the mincing method for isolation of adipose-derived stem cells from pregnant women fat. *Cytotechnology*, 70 (1): 55-66, 2018. DOI: 10.1007/s10616-017-0162-8
- 27. Crossmann G:** A modification of Mallory's connective tissue stain with a discussion of the principles involved. *Anat Rec*, 69, 33-38, 1937. DOI: 10.1002/ar.1090690105
- 28. Adams EJ, Gren JA, Clark AH, Youngson JH:** Comparison of different scoring systems for immunohistochemical staining. *J Clin Pathol*, 52, 75-77, 1999. DOI: 10.1136/jcp.52.1.75
- 29. Wolthers M, Moldovan M, Binderup T, Schmalbruch H, Krarup C:** Comparative electrophysiological, functional, and histological studies of nerve lesions in rats. *Microsurgery*, 25 (6): 508-519, 2005. DOI: 10.1002/micr.20156
- 30. Mohammadi R, Sanaei N, Ahsan S, Masoumi-Verki M, Khadir F, Mokarizadeh A:** Stromal vascular fraction combined with silicone rubber chamber improves sciatic nerve regeneration in diabetes. *Chin J Traumatol*, 18 (4): 212-218, 2015. DOI: 10.1016/j.cjtee.2014.10.005
- 31. Menovsky T, Beek JF:** Laser, fibrin glue, or suture repair of peripheral nerves: A comparative functional, histological and morphometric study in the rat sciatic nerve. *J Neurosurg*, 95 (4): 694-699, 2001. DOI: 10.3171/jns.2001.95.4.0694
- 32. Shamel J, Meyer VE, Bachem U:** Glueing of peripheral nerves with fibrin: Experimental studies. *J Reconstr Microsurg*, 3 (3): 211-218, 1987. DOI: 10.1055/s-2007-1006987
- 33. Gramsbergen A, Ijkema-Paassen J, Meek MF:** Sciatic nerve transection in the adult rat: Abnormal EMG patterns during locomotion by aberrant innervation of hindleg muscles. *Exp Neurol*, 161 (1): 183-193, 2000. DOI: 10.1006/exnr.1999.7233
- 34. Georgiou M, Golding JP, Loughlin AJ, Kingham PJ, Phillips JB:** Engineered neural tissue with aligned, differentiated adipose-derived stem cells promotes peripheral nerve regeneration across a critical sized defect in rat sciatic nerve. *Biomaterials*, 37, 242-251, 2015. DOI: 10.1016/j.biomaterials.2014.10.009
- 35. Isaacs JE, McDaniel CO, Owen JR, Wayne JS:** Comparative analysis of biomechanical performance of available "nerve glues". *J Hand Surg*, 33 (6): 893-899, 2008. DOI: 10.1016/j.jhsa.2008.02.009
- 36. Martins RS, Siqueira MG, Da Silva CF, Plese JP:** Overall assessment of regeneration in peripheral nerve lesion repair using fibrin glue, suture, or a combination of the 2 techniques in a rat model. Which is the ideal choice? *Surg Neurol*, 64, S1:10-S1:16, 2005. DOI: 10.1016/j.surneu.2005.04.022
- 37. Hüseyinoğlu N, Özyayın İ, Yayla S, Yıldırım CH, Aksoy Ö, Kaya M, Şengöz A, Taşdemiroğlu E:** Electrophysiological assessment of the effects of silicone tubes and hyaluronic acid on nerve regeneration in rats with sciatic neurolysis. *Kafkas Univ Vet Fak Derg*, 18 (6): 917-922, 2012. DOI: 10.9775/kvfd.2012.6373
- 38. Sta M, Cappaert NLM, Ramekers D, Baas F, Wadman WJ:** The functional and morphological characteristics of sciatic nerve degeneration and regeneration after crush injury in rats. *J Neurosci Methods*, 222, 189-198, 2014. DOI: 10.1016/j.jneumeth.2013.11.012
- 39. Martins RS, Siqueira MG, Da Silva CF, De Godoy BO, Plese JPP:** Electrophysiological assessment of regeneration in rat sciatic nerve repair using suture, fibrin glue or a combination of both techniques. *Arq Neuropsiquiatr*, 63 (3-A): 601-604, 2005. DOI: 10.1590/s0004-282x2005000400009