

## **Innervation of the Shoulder Joints in Turkish Shepherd Dogs (Karabash-Kangal), Curly Sheep and Native Hair Goats: An Anatomic Study**

<sup>1</sup>Bestami Yilmaz and <sup>2</sup>Ali Bahadir

<sup>1</sup>Faculty of Veterinary Medicine, University of Harran, Sanliurfa, Turkey

<sup>2</sup>Faculty of Veterinary Medicine, University of Uludag, Bursa, Turkey

**Abstract:** This study is carried out with five Turkish shepherd dog (*Canis familiaris*), five curly sheep (*Ovis aries*) and five native hair goats (*Capra hircus*) which were adult and in different gender, macroanatomical, subgross and comprehensive research of sensible nerves (n.) innervating shoulder joint capsule was aimed. The shoulder joint capsule was found to be innervated by axillary and suprascapular nerves in Turkish shepherd dog, curly sheep and native hair goats in macroscopic and subgross analysis. The articular branch of axillary nerve was detected to generally terminate in joint capsule with 3 branches from caudolateral and suprascapular nerve was detected to terminate in joint capsule with 1 branch from lateral. In conclusion, number of the articular branches was found to be more in Turkish shepherd dogs and native hair goats compared to curly sheep. These differences were considered to be related to stated two species being more athletic and faster than curly sheep.

**Key words:** Shoulder joint, joint capsule, innervation, Turkish shepherd, dog, sheep, Turkey

---

### **INTRODUCTION**

Many researches were done in humans (Lee *et al.*, 1992; Uzun and Bilgic, 1999), mammals and nonmammals (Magilthon *et al.*, 1968; Waluszewska-Bubien and Pospieszny, 1982; Booth, 1991) about peripheral nerves and morphology of brachial plexus. Histological, physiological (Freeman and Wyke, 1967; Heppelmann, 1997), anatomical (Yilmaz and Bahadir, 2009), morphometric (Lee *et al.*, 1992) and ultrasonographic (Sheppard *et al.*, 1998; Demondion *et al.*, 2003) studies were also added to these morphological researches in following years. In the studies held in previous years, ease of motion was put forward to be gained again by the animal by providing a rapid analgesia after the denervation process done by removal of periost surrounding joint capsule (Kinzel *et al.*, 1998, 2002; Braun *et al.*, 2003). This condition increased the importance of the studies about innervation of capsule.

For this reason, both adding a new study to the ones done about nervous system and fulfilling the need for morphological informations about related animal species were aimed with this study aiming at macroanatomical, subgross and comprehensive analysis of the nerves innervating shoulder joint capsule in Turkish shepherd dog (Karabas-Kangal), curly sheep and native hair goats.

### **MATERIALS AND METHODS**

Adult and different gender of five Turkish shepherd dog (2 males, 3 females; mean weight 34.6±1.52 kg), five curly sheep (1 male, 4 females; mean weight 35.8±4.95 kg) and five native hair goats (2 males, 3 females; mean weight 28.4±0.71 kg) which were obtained from Bursa region and being used for practice cadavers in Department of Anatomy were used as research materials. The animals which were anesthetized using preparations including xylazin HCl (Rompun 2%®, Bayer, Turkey) and ketamin HCl (Ketalar®, Parke-Davis, Turkey) were injected intravenous heparin sulphate (Liquemine®, Roche, Turkey) in order to prevent intravascular coagulation. The common carotid artery was exposed with an incision done from jugular sulcus region. Blood of the animals were emptied with a partial incision done in this vessel. Animals which were fixed with 10% formaldehyde subsequently were kept in pools until dissection process. Follow of the nerves branching from brachial plexus was realized from both sides of the body and by reaching the joints of each side from medial and lateral for macroscopic examination of the nerves terminated in joint capsule. Dissection of fine and fragile ramus articularis was made under Nikon SMZ-10 stereomicroscope and photographed by a Nikon D100 (Nikon Corporation, Japan) digital camera. Nomina Anatomica Veterinaria

(ICVGAN, 2005) was utilized for anatomic terms used in the study. The experimental Animals Ethical Committee of Veterinary Faculty of Uludag University approved all experimental protocols (No. 2004/1).

**RESULTS AND DISCUSSION**

Joint capsule was detected to be innervated by ramus articularis originated from axillary and suprascapular nerves as the result of macroscopic and subgross analysis of shoulder joint capsule of Turkish shepherd dogs, curly sheep and native hair goats (Table 1).

**Articular branches of axillary nerve:** The axillary nerve was seen to proceed towards margo scapularis of the scapula by crossing over the distal part of the subscapular muscle after leaving brachial plexus. It was seen to swirl to lateral between subscapular muscle and subscapular artery and give a branch or branches to shoulder joint capsule while it was proceeding in the

caudal of shoulder joint. Many muscular branches were seen to branch out before joint capsule branches were branched out from axillary nerve.

The axillary nerve was seen to give articular branches to shoulder joint capsule in all analysed animal species. Number of these branches was found as 2 (40%) in 4 of the pieces, 3 (50%) in five pieces and 4 (10%) in one piece in Turkish shepherd dogs. While number of articular branches was found as 2 (40%), 3 (40%) and 4 (20%) in curly sheep, these numbers were found to be 2 (40%) and 3 (40%) in four pieces for each, 4 (10%) in one piece and 5 (10%) in one piece in native hair goats.

In Turkish shepherd dogs, articular branches out from axillary nerve were detected to be localized in caudolateral site of joint capsule. The nerve was detected in both caudal and caudolateral sites only in the left leg of the dog number 3.

The articular branches were found to terminate in various points of the joint capsule in curly sheep and native hair goats. In sheep, target points of these branches were detected to be caudolateral of joint capsule in 6 pieces, caudal part in 2 pieces, both caudal and caudolateral part in 2 pieces. The axillary nerve was detected to give articular branches to caudolateral part of the capsule in 6 pieces, to caudal part in 2 pieces and to caudal and caudolateral parts in 2 pieces of native hair goats (Fig. 1).

**Articular branches of suprascapular nerve:** The suprascapular nerve located in the cranial of brachial plexus was seen to travel together with circumflex scapular artery and vein. It was detected to swirl to lateral from anterior side of scapula after crossing between subscapular muscle and supraspinatus muscle in the

Table 1: Distribution of branches in cadaver specimens

Specimens	Side	Axillary branches number and location	Suprascapular branches number and location
<b>Turkish shepherd dogs</b>			
Dog-1	R	2, Caudolateral	1, Lateral
	L	2, Caudolateral	1, Lateral
Dog-2	R	3, Caudolateral	2, Lateral
	L	3, Caudolateral	2, Lateral
Dog-3	R	3, Caudolateral	1, Lateral
	L	4, Caudolateral and caudal	1, Lateral
Dog-4	R	2, Caudolateral	1, Lateral
	L	2, Caudolateral	1, Lateral
Dog-5	R	3, Caudolateral	2, Lateral
	L	3, Caudolateral	2, Lateral
<b>Curly sheeps</b>			
Sheep-1	R	3, Caudal and caudolateral	1, Lateral
	L	3, Caudal and caudolateral	1, Lateral
Sheep-2	R	2, Caudolateral	1, Lateral
	L	2, Caudolateral	1, Lateral
Sheep-3	R	4, Caudolateral	1, Lateral
	L	4, Caudolateral	1, Lateral
Sheep-4	R	3, Caudolateral	1, Lateral
	L	3, Caudolateral	1, Lateral
Sheep-5	R	2, Caudal	1, Lateral
	L	2, Caudal	1, Lateral
<b>Native hair goats</b>			
Goat-1	R	3, Caudolateral	1, Lateral
	L	3, Caudolateral	1, Lateral
Goat-2	R	2, Caudolateral	1, Lateral
	L	2, Caudolateral	1, Lateral
Goat-3	R	2, Caudolateral	1, Lateral
	L	2, Caudolateral	1, Lateral
Goat-4	R	5, Caudal and caudolateral	2, Lateral
	L	4, Caudal and caudolateral	2, Lateral
Goat-5	R	3, Caudal	1, Lateral
	L	3, Caudal	1, Lateral

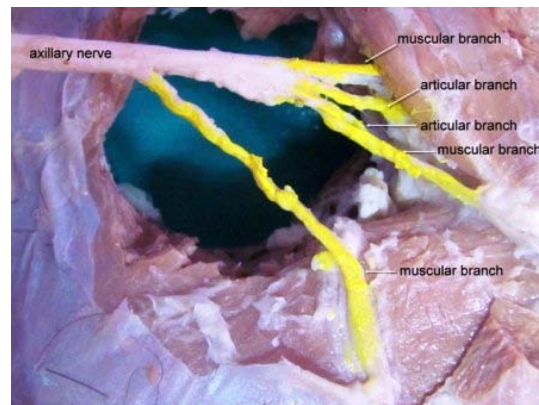


Fig. 1: Innervations of the shoulder joint in native hair goats by the axillary nerve. Lateral view of the right shoulder

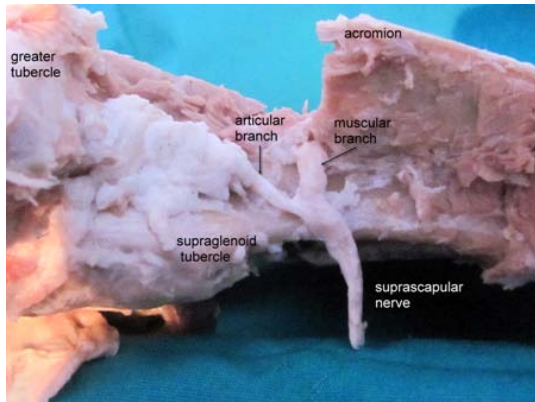


Fig. 2: Innervations of the shoulder joint in curly sheep by the suprascapular nerve. Cranial view of the right shoulder

medial of scapula. It was seen to give nerve branches taking part in innervation of shoulder joint at the level of approximately spina scapulae after giving branches innervating the supraspinatus and infraspinatus muscle (Fig. 2).

In Turkish shepherd dogs, number of articular branches was found as 1 (60%) in 6 pieces and 2 (40%) in 4 pieces. While number of articular branches going to joint capsule was found to be 1 (100%) in all cases in curly sheep, number of these branches was detected as 1 (80%) in 8 pieces and 2 (20%) in 2 pieces.

Dissection of articular branches out from suprascapular nerve was realized hardly due to intensive fat and connective tissue at the level of cranial part of collum scapulae. All branches terminating in joint capsule by originating from suprascapular nerve were seen to be localized in proximo-lateral site of shoulder joint capsule.

In literature, shoulder joint capsule was reported to be generally innervated by axillary nerve in domestic mammals. In cattles, this joint capsule was reported to be innervated by only axillary nerve or by both axillary and suprascapular nerves. Whereas in sheep, musculocutaneous nerve was reported to contribute to innervation in addition to stated nerves.

In the studies of Staszuk held in dogs, Gezici held in sheep and goats, Rudinger held in humans, shoulder joint capsule was reported to be innervated by axillary and suprascapular nerves. In the study, shoulder joint capsule was detected to be innervated by axillary nerve and suprascapular nerve in Turkish shepherd dogs, curly sheep and native hair goats. It was found in concordance with the studies of Gigov held in cattles, held in sheep and goats and Staszuk held in dogs.

In this study, axillary nerve was seen to travel together with radial nerve at the beginning after leaving

brachial plexus to draw away from radial nerve between subscapular artery and caudal side of subscapular muscle and to give more than one branches to caudal or caudolateral of shoulder joint by swirling towards lateral. This course of axillary nerve was found to be in concordance with literature (Budras *et al.*, 2002).

In the study of Gigov on cattles, he reported that axillary nerve gave a total of 7 branches of which 3 were to medial and 2 were to caudal and 2 were to lateral during its course around shoulder joint, Staszuk reported that number of the branches coming to joint capsule varied between 1 and 5 in dogs, Gahring (1985) reported that this number was 3. The axillary nerve was detected to give ramus articularis to shoulder joint capsule in all pieces analysed in this study.

These branches were observed to terminate in caudal and caudolateral of the joint and the number was observed to vary between 2 and 4 in Turkish shepherd dogs. Whereas the nerve was detected to give 2-5 branches generally in caudolateral and partially in caudal of the joint in curly sheep and native hair goats. Additionally, the knowledge that the entrance sites to joint capsule being similar, however that number and sites leaving main body being variable was detected to support literature.

Although, axillary nerve was definitely reported to contribute to innervation of shoulder joint capsule, sufficient information could not be obtained on whether suprascapular nerve contributed to innervation of joint capsule. It is stated that suprascapular nerve gave 1 branch contribute to shoulder joint innervation at the level of spina scapulae during its course in sheep and goats whereas in canis it was stated that it gives 1 branch to proximo-lateral of joint capsule (Gahring, 1985; Kitchell and Evans, 1993) or more than one branches to lateral (Ghoshal, 1975). Staszuk detected 1 or 2 branches of suprascapular nerve in proximo-lateral part of the joint capsule in 18 of 19 canis pieces.

In the study, suprascapular nerve gave sometimes 1 branch, sometimes 2 branches for innervation of joint capsule in dogs, sheep and goats. These results support the findings of researchers who reported that the nerve gave 1 branch (Gahring, 1985; Kitchell and Evans, 1993) or more than one branches (Ghoshal, 1975; Anderson *et al.*, 1994) to joint capsule. Staszuk reported that the reason for insufficient or variable information about contribution of suprascapular nerve to innervation of shoulder joint was related to anatomic structure of shoulder joint. We conclude that cover of articular branches of the nerve by processus hamatus and a big amount of fat tissue in this region reinforce this possibility.

## CONCLUSION

In the study, shoulder joint capsule was seen to be innervated by axillary and suprascapularis nerves in Turkish shepherd dogs, curly sheep and native hair goats. The articular branches of axillary nerve was detected to be included in joint capsule with 3 branches from caudolateral and articular branches of suprascapular nerve was detected to be included in joint capsule with 1 branch from lateral. The reason for number of articular branches going to joint capsule being more in Turkish shepherd dogs and native hair goats compared to curly sheep was considered to be related to these two species of domestic mammals being more athletic and faster than sheep.

## REFERENCES

- Anderson, W., W.D. Anderson, B.G. Anderson and B.J. Smith, 1994. Atlas of Canine Anatomy. Lea and Febiger Publishers, Philadelphia, ISBN-13: 9780812115352, pp: 1230.
- Booth, K.K., 1991. The brachial plexus in the vervet monkey (*Cercopithecus pygerythrus*). J. Med. Primatol., 20: 23-28.
- Braun, D., O. Lautersack, E. Schimke and D. Gentsch-Braun, 2003. Dorsal denervation of the hip joint capsule in dogs. Kleintierpraxis, 48: 211-218.
- Budras, K.D., P.H. McCarthy, W. Fricke and R. Richter, 2002. Anatomy of the Dog. 4th Edn., Schlutersche Verlagsanstalt, Hannover.
- Demondion, X., P. Herbinet, N. Boutry, C. Fontaine, J.P. Francke and A. Cotton, 2003. Sonographic mapping of the normal brachial plexus. AJNR Am. J. Neuroradiol., 24: 1303-1309.
- Freeman, M.A. and B. Wyke, 1967. The innervation of the knee joint. An anatomical and histological study in the cat. J. Anat., 101: 505-532.
- Gahring, D.R., 1985. A modified caudal approach to the canine shoulder joint. J. Am. Anim. Hosp. Assoc., 21: 613-618.
- Ghoshal, N.G., 1975. Spinal Nerves. In: Sisson and Grossman's the Anatomy of the Domestic Animals, Getty, R. (Ed.). 4th Edn., W.B. Saunders Company, Philadelphia, pp: 1127-1135.
- Heppelmann, B., 1997. Anatomy and histology of joint innervation. J. Peripher. Nerv. Syst., 2: 5-16.
- ICVGAN, 2005. Nomina Anatomica Veterinaria. 5th Edn., International Committees on Veterinary Gross Anatomical Nomenclature, New York.
- Kinzel, S., R. Fasselt, A. Prescher, C. Selzer, D.G. von Keyserlingk and W. Kupper, 1998. Sensory innervation of the hip joint capsule in dogs. Tierarztl. Prax. Ausg. K. Klientiere Heimtiere, 26: 330-335.
- Kinzel, S., S. Hein, C. von Scheven and W. Kupper, 2002. 10 years experience with denervation of the hip joint capsule for treatment of canine hip joint dysplasia and arthrosis. Berl. Munch. Tierarztl. Wochenschr., 115: 53-56.
- Kitchell, R.L. and H.E. Evans, 1993. The Spinal Nerves. In: Miller's Anatomy of the Dog, Evans, H.E. (Ed.). 3rd Edn., W.B. Saunders, Philadelphia, London, pp: 829-893.
- Lee, H.Y., I.H. Chung, W.S. Sir, H.S. Kang and H.S. Lee *et al.*, 1992. Variations of the ventral rami of the brachial plexus. J. Korean. Med. Sci., 7: 19-24.
- Magilthon, J.H., R. Getty and N.G. Ghoshal, 1968. A comparative morphological study of the brachial plexus of domestic animals (goat, sheep, horse). Iowa State J. Sci., 42: 245-279.
- Sheppard, D.G., R.B. Iyer and M.J. Fenstermacher, 1998. Brachial plexus: Demonstration at US. Radiology, 208: 402-406.
- Uzun, A. and S. Bilgic, 1999. Some variations in the formation of the brachial plexus infants. Turk. J. Med. Sci., 29: 573-577.
- Waluszewska-Bubien, A. and N. Pospieszny, 1982. Morphometric study of the brachial plexus in bustard (*Otis tarda* L., 1758). Folia Morphol., 41: 89-102.
- Yilmaz, B. and A. Bahadir, 2009. Nerves innervating articular capsule of elbow joints in Turkish shepherd dogs (Karabas-Kangal), curly sheep and native hair goats: An anatomic study. Kafkas Univ. Vet. Fakultesi Dergisi, 15: 835-840.