

Statistical Shape Analysis of Differences in the Shape of the Corpus Callosum Between Genders

SENEM TURAN OZDEMIR,^{1*} ILKER ERCAN,² OZDEMIR SEVINC,³ IBRAHIM GUNEY,⁴ GOKHAN OCAKOGLU,² ELIF ASLAN,⁴ AND CAGATAY BARUT⁵

¹Department of Anatomy, Faculty of Medicine, Uludag University, Bursa, Turkey

²Department of Biostatistics, Faculty of Medicine, Uludag University, Bursa, Turkey

³Department of Anatomy, Faculty of Medicine, Düzce University, Duzce, Turkey

⁴Department of Mathematics, Faculty of Arts & Sciences, Uludag University, Bursa, Turkey

⁵Department of Anatomy, Faculty of Medicine, Zonguldak Karaelmas University, Zonguldak, Turkey

ABSTRACT

Sexual dimorphic characteristics, which play an important role in human evolution studies and biological research, can be studied morphologically and metrically. Geometric morphometrics allows a better assessment of morphological characteristics. Statistical shape analysis has a long history in neuroanatomical and other research. The aim of this study was to identify shape differences of the corpus callosum between genders. Landmark coordinate data were collected from two-dimensional magnetic resonance imaging scans of 93 homogeneously aged patients, 45 men and 48 women. These data were analyzed using Euclidean distance matrix analysis and thin plate spline analysis. The general shape variability of the corpus callosum of men was greater than that of women (men, 0.134; women, 0.097). We found no significant difference between sexes in the general shape of the corpus callosum, but we did find significant differences in the distances between some landmarks. Deformation of the corpus callosum between men to women was mainly detected in the posterior of the corpus callosum. These results serve as a reference for future studies on shape alterations of the corpus callosum associated with certain conditions. *Anat Rec*, 290:825–830, 2007. © 2007 Wiley-Liss, Inc.

Key words: corpus callosum; sexual dimorphism; statistical shape analysis; geometric morphometrics; EDMA

The corpus callosum (CC) is the major commissural pathway between the brain hemispheres and plays an integral role in relaying sensory, motor, and cognitive information from homologous regions in the two hemispheres. Many neurological studies indicate that the size and shape of the CC are related to gender, age, and neurodegenerative diseases, among other factors. The sexual dimorphism of the CC has been reported from postmortem and magnetic resonance imaging (MRI) studies, but this conclusion has remained controversial since the original report by DeLacoste-Utamsing and Holloway (1982), who found that adult human women had a larger splenium.

Statistical shape analysis, a relatively new method in biological research, compares body forms by using specific landmarks determined by anatomical prominences.

*Correspondence to: Senem Turan Ozdemir, Department of Anatomy, Faculty of Medicine, Uludag University, Gorukle Campus, 16059, Bursa, Turkey. Fax: 90-224-4428023. E-mail: senem@uludag.edu.tr

Received 12 December 2006; Accepted 9 April 2007
DOI 10.1002/ar.20558
Published online 30 May 2007 in Wiley InterScience (www.interscience.wiley.com).

Landmark-based measurement, based on size and shape information, has a long history in neuroanatomical and other research. Landmark location analysis has been used in forensics (De Greef et al., 2006), computer-assisted neurosurgery (Aldridge et al., 2002), anthropological studies (Jonke et al., 2003; Pretorius et al., 2006; Veleminska et al., 2006; Ercan et al., 2007), MRI-based morphological analyses of the whole brain (Bookstein et al., 2001), landmark-based registration and measurement in MRI (Aldridge et al., 2002, 2005a,b), and psychiatric disorder assessment (Tibbo et al., 1998; DeQuardo et al., 1999). The quantitative morphological assessment of individual brain structures is often based on global volume and area measurements, which are intuitive features that may explain atrophy or dilation due to illness. On the other hand, structural changes at specific locations are not sufficiently reflected in volume and area measurements.

Shape analysis has, thus, become of increasing interest to the neuroimaging community. Many studies have measured anatomical brain structures quantitatively, in terms of volume, area, width, and length, but only a few have performed shape analysis using landmarks. Several procedures for obtaining shape information from landmark data have been proposed. For example, Euclidean Distance Matrix Analysis (EDMA) is a landmark-based method that uses landmark coordinate data to calculate all possible linear distances among landmarks, creating a form matrix for each object (Burrows et al., 1999). The coordinate system-invariant properties of EDMA results make EDMA biologically and statistically advantageous (Theodore and Richtsmeier, 1998). Bookstein (1989) developed thin-plate spline (TPS) analysis as a morphometric approach for comparing landmark configurations in two or more specimens. A TPS analysis produces highly informative figures that greatly aid in the interpretation of shape changes (Hammer and Harper, 2006).

We used EDMA and TPS techniques to examine gender-based changes in the shape of the CC. A configuration of landmarks was identified in brain MRI midsagittal sections. The landmarks chosen to determine the shape differences of the CC had been identified in previous studies (Tibbo et al., 1998; DeQuardo et al., 1999).

METHODS AND MATERIALS

Subjects

The study was carried out by means of MRI scans of 93 homogeneously aged patients, including 45 men (age, 43.11 ± 16.27 yr, mean \pm SD) and 48 women (37.04 ± 14.26 yr).

Cranial MRI scans of patients who were admitted to Uludag University, School of Medicine, Department of Radiology with several complaints between July 1998 and August 1999 were reviewed retrospectively. MRI scans of 93 patients (45 men, 48 women) with no neuropathology were evaluated. All the patients gave consent before the diagnostic procedures during their hospital admittance. Table 1 shows the distribution of the patients by gender and mean age. Given the effect of age on CC shape, the distribution of the age variable by gender was tested, using both a *t*-test to compare means and a χ^2 to analyze the distribution by age groups. Patients with a history of neuroendocrine disorders,

TABLE I. Distribution of age groups according to sex and mean age values

	Male	Female	Significant
Age group	N (%)	N (%)	
11–20	4 (8.9)	6 (12.5)	$P = 0.125$
21–30	6 (13.3)	11 (22.9)	
31–40	9 (20)	15 (31.3)	
41–50	12 (26.7)	7 (14.6)	
51–60	5 (11.1)	5 (10.4)	
61–70	9 (20)	4 (8.3)	
N	45	48	$P = 0.059$
Mean	43.11	37.04	
SD	16.27	14.26	

cranial mass, and multiple sclerosis affecting gross neural formation or brain operations, radiotherapy, or chemotherapy were excluded.

MRI Examinations

MRI scans of the subjects were obtained at 1 T (Magnetom Impact), as sagittal T1-weighted spin echo images (repetition time, 570 msec; echo time, 15 msec), with one excitation. The slice thickness was 5 mm, with a 0.2-mm skip between slices and a 192×256 matrix.

Collection of Two-Dimensional CC Landmarks

From the sagittal planes, the midsagittal section that most clearly displayed the cerebral aqueduct, CC, and superior colliculus was selected manually. The anterior to posterior commissure line and interhemispheric fissure were identified and used to align the brains of all subjects to a standard position. In this image, nine landmarks on the CC were identified (Fig. 1): 1 = anterior-most point of CC; 2 = CC–fornix junction; 3 = interior notch of splenium; 4 = inferior tip of splenium; 5 = posteriormost point of CC; 6 = topmost point of splenium, 7 = topmost point of CC; 8 = posterior angle of genu; and 9 = posterior tip of genu. Table 2 describes the landmarks. The landmarks were marked on the digital images by using TPSDIG 2.04 software. These landmark points fall within the criteria outlined in Bookstein (1991) and include extreme points or terminals and maxima of curvature or other local shape processes.

The computation proceeded in four steps. We first identified landmarks from the series of homologous MRI scans and then determined landmark coordinates. Next, we ascertained the mean landmark configurations of men and women and evaluated general and local shape differences. In the last step, we determined shape deformations from men to women by the TPS method, using average shapes obtained by Procrustes analysis. The shape deformations from men to women were expressed using expansion and contraction grids.

Statistical Analysis

The homogeneity of variance–covariance matrices was examined using the Box-M test (Dryden and Mardia, 1998). For existing homogeneities of variance–covariance matrices, the EDMA I method was used; otherwise, the EDMA II method was preferred for shape analysis.

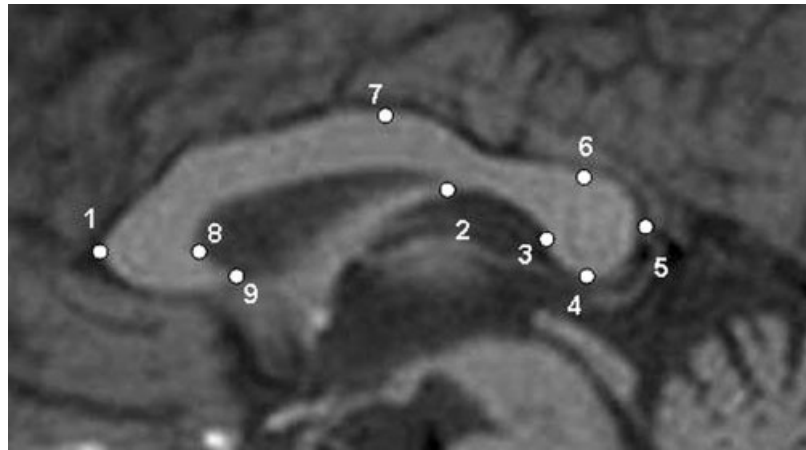


Fig. 1. Landmarks that were used in statistical shape analysis.

TABLE II. Landmark definitions

Landmark	Landmark definition
1	Anteriormost point of CC
2	CC–fornix junction
3	Interior notch of splenium
4	Inferior tip of splenium
5	Posteriormost point of CC
6	Splenium topmost point
7	Topmost point of CC
8	Posterior angle of genu
9	Posterior tip of genu

CC, corpus callosum.

EDMA compares the forms or shapes of organisms that have been measured using two- or three-dimensional coordinates of homologous anatomical landmarks (Lele and Richtsmeier, 1991, 2001; Lele, 1993). EDMA uses landmark-coordinated data to calculate all possible linear distances among landmarks and creates a form matrix for each subject (Burrows et al., 1999).

For EDMA II, we used the geometric means of the distances among landmarks as scaling factors and standardized the form difference matrix for each sample by dividing each entry by the appropriate scaling factor. A parametric bootstrap technique (Monte Carlo) was used to create 1,000 resamples. We performed statistical tests on the null hypothesis of the equality of the shapes for subsets of landmarks and used confidence interval testing to evaluate the statistical significance of differences in individual linear distances (Cole, 2002). To obtain an overall measurement of shape variability, we considered the root mean square of Kendall’s Riemannian distance (ρ) to the mean shape (Dryden, 2004).

In the midsagittal cranial MRI view of the CC, the 9 (k) landmarks had 36 ($[k(k-1)]/2$) interlandmark distances, which were statistically compared. Owing to the heterogeneity of the variance–covariance matrices ($P < 0.001$), the EDMA II method was used to compare the gender differences. The shape deformation of the CC from men to women was evaluated using the TPS method, which was derived from a mathematical model used in computer graphics and applied to morphometrics by Bookstein (1989, 1991).

TABLE III. Interlandmark distances that were significantly different between men and women^a

Greater interlandmark distances in men ($P < 0.05$)	1–9, 4–6, 1–7, 4–8, 2–8, 4–7, 1–4, 1–2, 2–7, 5–6
Greater interlandmark distances in women ($P < 0.05$)	6–2, 6–9, 6–7, 6–8, 6–1, 2–3, 2–5, 4–5, 3–9

^aArrangement of the greater interlandmark distances.

RESULTS

No statistically significant differences in terms of age or age-group distributions were found between the sexes ($P > 0.05$). No statistically significant difference in terms of general shape in CC was found between the sexes. However, there were significant differences between the sexes in some of the interlandmark distances: 25% of the interlandmark distances were greater in women, and 28% were greater in men ($P < 0.05$; Table 3; Fig. 2).

The greater distances between landmarks in women were mainly in the posterior of the CC, whereas those in men were mainly in the anterior. The distances 1–5, involving the length of the CC; 1–8, corresponding to genu length; and 3–5, corresponding to splenium length, showed no difference between men and women. The general shape variability of the CC was higher in men than women (men, 0.134; women, 0.097).

Procrustes mean shapes were computed for TPS (Fig. 3). In accordance with the TPS method, the points exhibiting the most enlargement and shrinkage were labeled as deformations. The deformations from men to women were seen mainly in the posterior of the CC. Landmark 4 had the most enlargements, and landmark 2 had the most shrinkage. Figures 4 and 5 show the resulting TPS transformation grid, clarifying the direction and degree of compression and expansion.

DISCUSSION

Studies of sexual dimorphism in the shape of the CC have used a variety of methodologies for measurement and normalization, but have yielded disparate results. Statistical shape analysis is of increasing interest to the neuroimaging community because of its potential to locate morphological changes. Statistical studies of anatomical shape variations in populations are important for understanding the anatomical effects of diseases or

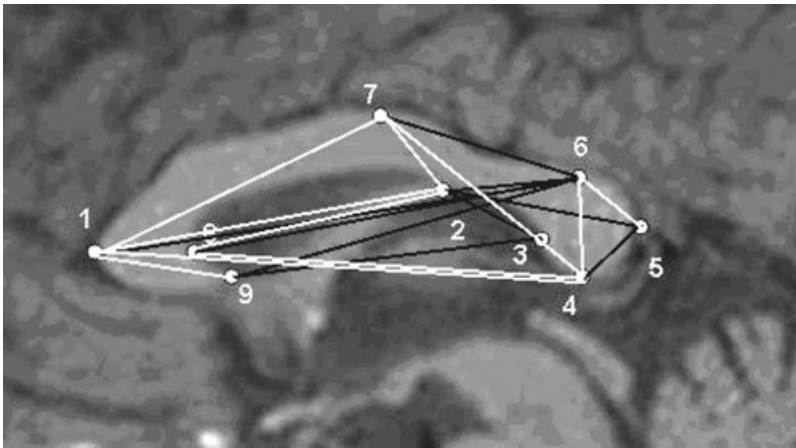


Fig. 2. Black lines indicate the interlandmark distances that were found to be greater in women. White lines indicate the interlandmark distances that were found to be greater in men.

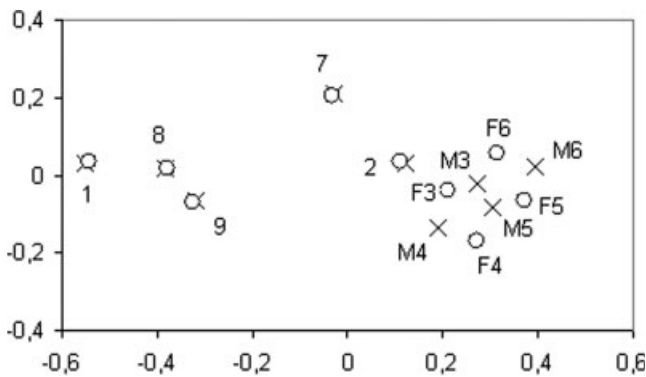


Fig. 3. Means of Procrustes shape for corpus callosum images of men (x) and women (o).

biological processes (Polina et al., 2001). Several procedures for obtaining shape information from landmark data have been proposed. In this study, we used the EDMA and TPS methods in the belief that evaluating general form differentiation in the CC by using homologous neuroanatomical landmarks is most relevant. Thus, this study is the first in which gender-based shape differences were evaluated using a landmark-based geometrical morphometric method in which all possible distances between landmarks were measured using previously determined neuroanatomical landmarks.

The sexual dimorphism of the CC was first suggested by DeLacoste-Utamsing and Holloway (1982), who found that adult human women had a larger splenium. Although most studies have found gender-based differences in the vicinity of the CC and its substructures (Witelson, 1989; Allen et al., 1991; Davatzikos and Resnick, 1998; Sullivan et al., 2001), some have not (Suganthi et al., 2003; Luders et al., 2006). For example, the size and shape of the posterior portions of the CC have been reported to be sexually dimorphic and related to cerebral dominance for speech and handedness (DeLacoste-Utamsing and Holloway, 1982; Witelson, 1985, 1989; Allen et al., 1991). Some investigators have reported that adult women have a more bulbous splenium with a larger area relative to brain size (DeLacoste-Utamsing and Holloway, 1982; Holloway and DeLacoste, 1986; Clarke et al., 1989; Allen et al., 1991).

Other investigators have found larger posterior callosal regions in men (Denenberg et al., 1991), as well as a larger callosal area (Clarke et al., 1989; Davatzikos and Resnick, 1998), genu (Witelson, 1989), and anterior trunk area (Witelson, 1989). The majority of studies have identified no differences between the sexes in general shape features; however, they have established differences in CC substructures connected with cognitive and functional differences between men and women. For example, in women, the wider splenium is in harmony with the homotopic arrangement of the CC, whereas the wider genu in men is related to increased motor coordination (Davatzikos and Resnick, 1998). Some empirical data suggest that sexual dimorphisms exist in callosal morphology, but these findings have not been consistently replicated. One possible reason for the continuing controversy may be the lack of standards in callosal analysis.

Several recent studies have applied EDMA and TPS analyses (Singh et al., 1997; Baccetti et al., 1999; Burrows et al., 1999; Aldridge et al., 2002, 2005a,b; Pretorius et al., 2006; Ercan et al., 2007), but those in which the shape of the CC was evaluated by geometrical morphometrics generally examined the effects of neuropsychiatric diseases (Tibbo et al., 1998; DeQuardo et al., 1999; Bookstein et al., 2001, 2002; Frumin et al., 2002). In a study comparing schizophrenic patients with a normal population, form analysis evaluation of the differences and shape deformations in average landmark configurations found statistical differences in the posterior of the CC and in superior brain formations between the two populations (DeQuardo et al., 1999). Another study used a morphometric method to demonstrate an effect of fetal alcohol syndrome on the geometric form of the CC and subcortical formations (Bookstein et al., 2001). A study using statistical shape analysis to evaluate the shape and dimensions of the CC in male schizophrenic patients found no differences in the form of the CC between the patient and control groups (Tibbo et al., 1998).

We used nine landmarks on the CC for shape analysis and found no differences in general shape features between the sexes. However, we did find significant differences in the distances between some landmarks related to CC substructures. Although most of the distances that were greater in women were those between landmarks in the posterior of the CC, we found no

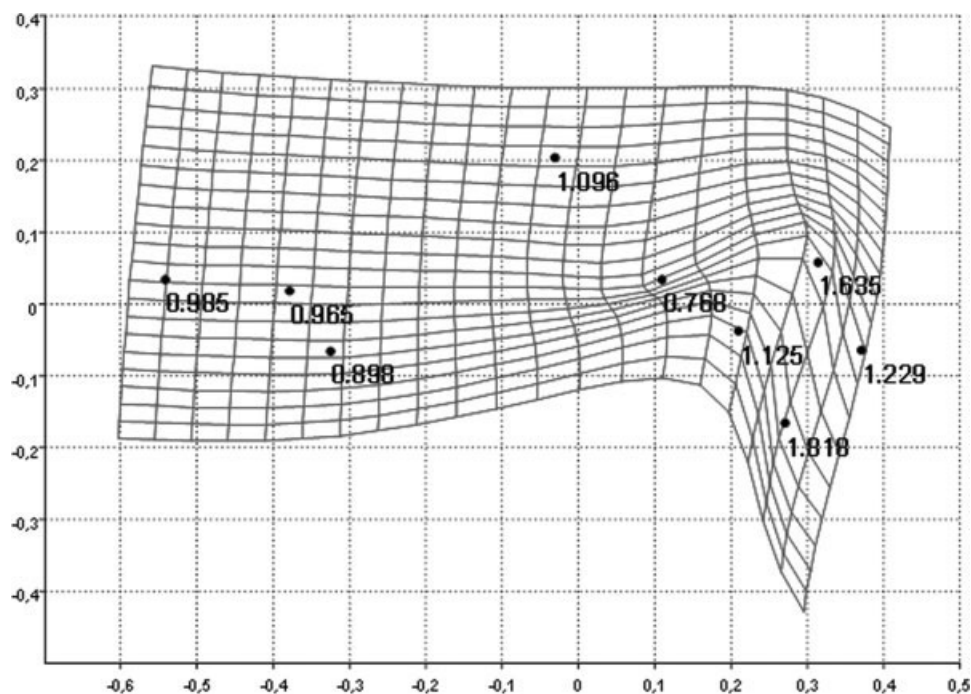


Fig. 4. Thin-plate spline demonstrating shape deformation from male to female average shape. Expansion factors at the landmarks are shown numerically (expansion factors larger than one). Note the compression in the anterior region, and expansion in the posterior.

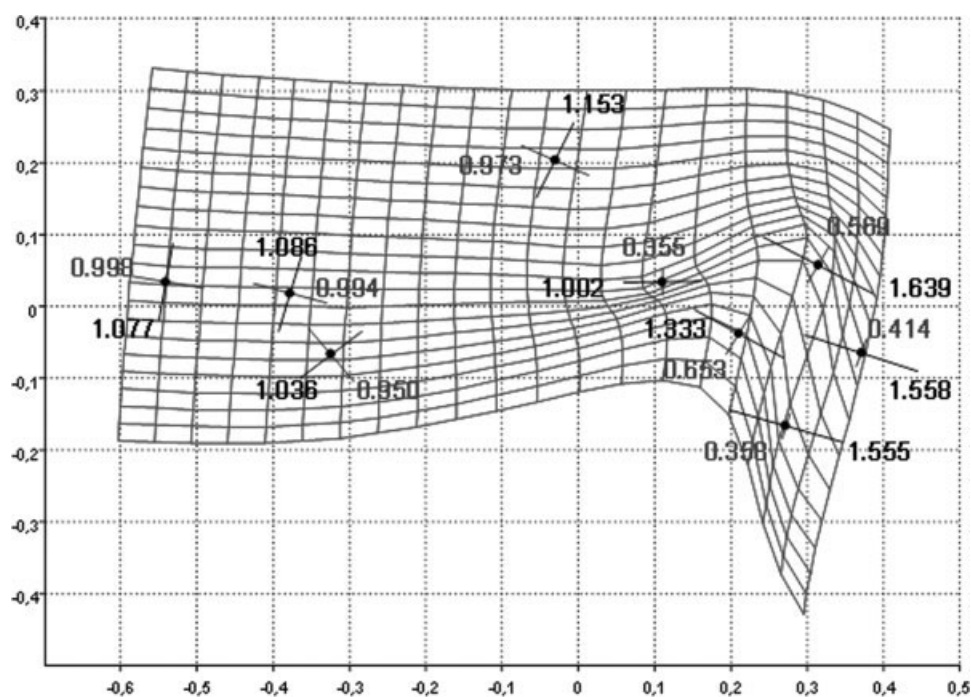


Fig. 5. Principal deformations of the transformation at each landmark.

gender-based differences with respect to the splenium. The splenium length previously reported to display a gender difference was the distance measured between landmarks 3–5 in our study; however, we did not detect a gender difference. Most of the differences that were

greater in men were those between landmarks in the anterior of the CC. We found no significant difference between genders in the genu.

The general shape variability was higher in men. We suggest that the general shape variability of the CC of

men, which was greater than that of women, may be related with the cognitive, sensitive, and motor differences between genders. Thus, this result needs detailed investigation in further studies.

The TPS method evaluates shape deformation as the most enlarged or shrunken fields. Among recent TPS analyses, Baccetti et al. (1999) reported on the treatment effects of rapid maxillary expansion and face mask therapy in early Class III malocclusions. Singh et al. (1997) applied TPS in a comparison of cranial base configurations between subjects with Class III malocclusions and Class I controls. We defined the deformation of the CC shape from men to women as excessive expansion in the inferior tip of the splenium or excessive shrinkage in the CC–fornix junction.

In conclusion, our landmark-based methodology detected no gender-based differences in the overall shape of the CC but did find regional differences between the sexes. This study may serve as a reference for future studies on shape alterations of the CC associated with certain medical conditions.

LITERATURE CITED

- Aldridge K, Marsh JL, Govier D, Richtsmeier JT. 2002. Central nervous system phenotypes in craniostenosis. *J Anat* 201:31–39.
- Aldridge K, Kane AA, Marsh JL, Panchal J, Boyadjiev SA, Yan P, Govier D, Ahmad W, Richtsmeier JT. 2005a. Brain morphology in nonsyndromic unicoronal craniostenosis. *Anat Rec* 285A:690–698.
- Aldridge K, Kane AA, Marsh JL, Yan P, Govier D, Richtsmeier JT. 2005b. Relationship of brain and skull in pre- and postoperative sagittal synostosis. *J Anat* 206:373–385.
- Allen LS, Richey MF, Chai YM, Gorski RA. 1991. Sex differences in the corpus callosum of the living human being. *J Neurosci* 11:933–942.
- Baccetti T, Franchi L, McNamara JA Jr. 1999. Thin-plate spline analysis of treatment effects of rapid maxillary expansion and face mask therapy in early class III malocclusions. *Eur J Orthod* 21:275–281.
- Bookstein FL. 1989. Principal warps: thin-plate splines and the decomposition of deformations. *IEEE Trans Pattern Anal Machine Intell* 11:567–585.
- Bookstein FL. 1991. *Morphometrics tools for landmark data*. New York: Cambridge University Press.
- Bookstein FL, Sampson PD, Streissguth AP, Connor PD. 2001. Geometric morphometrics of corpus callosum and subcortical structures fetal-alcohol-affected brain. *Teratology* 64:4–32.
- Bookstein FL, Sampson PD, Connor PD, Streissguth AP. 2002. Midline corpus callosum is a neuroanatomical focus of fetal alcohol damage. *Anat Rec* 269:162–174.
- Burrows AM, Richtsmeier JT, Mooney MP, Smith TD, Losken HW, Siegel MI. 1999. Three-dimensional analysis of craniofacial form in a familial rabbit model of nonsyndromic coronal synostosis using Euclidean distance matrix analysis. *Cleft Palate Craniofac J* 36:196–206.
- Clarke S, Kraftsik R, Van der Loos H, Innocenti GM. 1989. Forms and measures of adult and developing human corpus callosum: is there sexual dimorphism? *J Comp Neurol* 280:213–230.
- Cole TM III. 2002. Win EDMA: software for Euclidean distance matrix analysis. Verison 1.0.1 beta. Kansas City: University of Missouri – Kansas City School of Medicine.
- Davatzikos C, Resnick SM. 1998. Sex differences in anatomic measures of interhemispheric connectivity: correlations with cognition in woman but not men. *Cereb Cortex* 8:635–640.
- De Greef S, Claes P, Vandermeulen D, Mollemans W, Suetens P, Willems G. 2006. Large-scale in-vivo Caucasian facial soft tissue thickness database for craniofacial reconstruction. *Forensic Sci Int* 159(Suppl 1):126–146.
- DeLacoste-Utamsing C, Holloway RL. 1982. Sexual dimorphism in the human corpus callosum. *Science* 216:1431–1432.
- Denenberg VH, Kertesz A, Cowell PE. 1991. A factor analysis of the human's corpus callosum. *Brain Res* 548:126–132.
- DeQuardo JR, Keshavan MS, Bookstein FL, Bagwell WW, Green WDK, Sweeney JA, Haas GL, Tandon R, Schooler NR, Pettegrew JW. 1999. Landmark-based morphometric analysis of first-episode schizophrenia. *Biol Psychiatry* 45:1321–1328.
- Dryden I. 2004. Shapes: statistical shape analysis. R package version 1.0-8. Available at: <http://www.maths.nott.ac.uk/~ild/shapes>
- Dryden IL, Mardia KV. 1998. *Statistical shape analysis*. New York: John Wiley and Sons.
- Ercan I, Etoz A, Guney I, Ocakoglu G, Turan Ozdemir S, Kan I, Kahveci R. 2007. Statistical shape analysis of nose in Turkish young adults. *J Craniofac Surg* 18:219–224.
- Frumin M, Golland P, Kikinis R, Hirayasu Y, Salisbury DF, Hennen J, Dickey CC, Anderson M, Jolesz FA, Grimson WE, McCarley RW, Shenton ME. 2002. Shape differences in the corpus callosum in first-episode schizophrenia and first-episode psychotic affective disorder. *Am J Psychiatry* 159:866–868.
- Hammer O, Harper D. 2006. *Paleontological data analysis*. Oxford: Blackwell Publishing. p 122–128.
- Holloway RL, de Lacoste MC. 1986. Sexual dimorphism in the human corpus callosum: an extension and replication study. *Hum Neurobiol* 5:87–91.
- Jonke E, Schaefer K, Freudenthaler JW, Prossinger H, Bookstein FL. 2003. A cephalometric comparison of skulls from different time periods—the Bronze Age, the 19th century and the present. *Coll Antropol* 27:789–801.
- Lele S. 1993. Euclidean distance matrix analysis (EDMA): estimation of mean form and mean form difference. *Math Geol* 25:573–602.
- Lele S, Richtsmeier JT. 1991. Euclidean distance matrix analysis: a coordinate free approach to comparing biological shapes using landmark data. *Am J Phys Anthropol* 86:415–428.
- Lele S, Richtsmeier JT. 2001. An invariant approach to statistical analysis of shapes. New York: Chapman and Hall/CRC Press. p 162–163.
- Luders E, Narr KL, Zaidel E, Thompson PM, Jancke L, Toga AW. 2006. Parasagittal asymmetries of the corpus callosum. *Cereb Cortex* 16:346–354.
- Polina G, Grimson WEL, Shenton ME, Kikinis R. 2001. Deformation analysis for shaped based classification, information processing in medical imaging. In *Proceedings of IPMI: International Conference on Information Processing and Medical Imaging*, LNCS 2082:517–530.
- Pretorius E, Steyn M, Scholtz Y. 2006. Investigation into the usability of geometric morphometric analysis in assessment of sexual dimorphism. *Am J Phys Anthropol* 129:64–70.
- Singh GD, McNamara JA Jr, Lozanoff S. 1997. Thin-plate spline analysis of the cranial base in subjects with Class III malocclusion. *J Anat* 191:595–602.
- Suganthi J, Raghuram L, Antonisamy B, Vettivel S, Madhavi C, Koshi R. 2003. Gender- and age-related differences in the morphology of the corpus callosum. *Clin Anat* 16:396–403.
- Sullivan EV, Rosenbloom MJ, Desmond JE, Pfefferbaum A. 2001. Sex differences in corpus callosum size: relationship to age and intracranial size. *Neurobiol Aging* 22:603–611.
- Theodore MC III, Richtsmeier JT. 1998. A simple method for visualization of influential landmarks when using Euclidean distance matrix analysis. *Am J Phys Anthropol* 107:273–283.
- Tibbo P, Nopoulos P, Arndt S, Andreasen NC. 1998. Corpus callosum shape and size in male patients with schizophrenia. *Biol Psychiatry* 44:405–412.
- Witelson SF. 1985. The brain connection: the corpus callosum is larger in the left-handers. *Science* 229:665–668.
- Witelson SF. 1989. Hand and sex differences in the isthmus and genu of the human corpus callosum. *Brain* 112:799–835.
- Velemínska J, Katina S, Smahel Z, Sedláčková M. 2006. Analysis of facial skeleton shape in patients with complete unilateral cleft lip and palate: geometric morphometry. *Acta Chir Plast* 48:26–32.