

Bimanual microincisional phacoemulsification combined with viscocanalostomy plus deeper sclerectomy

MEHMET BAYKARA¹, OZGUR B. TİMUCİN²

¹Department of Ophthalmology, Uludag University School of Medicine, Bursa

²Department of Ophthalmology, Kurtalan State Hospital, Siirt - Turkey

PURPOSE. *The aim of the study was to evaluate the safety and effectiveness of a new technique, two-site bimanual microincisional cataract surgery combined with viscocanalostomy plus deeper sclerectomy (two-site bimanual MICS-VC-DS), in patients with cataract and glaucoma.*

METHODS. *Noncomparative, interventional case series. From December 2005 to October 2007, a consecutive series of 12 patients (12 eyes) with uncontrolled primary open angle glaucoma (POAG) and cataract have undergone two-site bimanual MICS-VC-DS. Postoperative evaluation included visual acuity (VA), intraocular pressure (IOP), average retinal nerve fiber layer (RNFL) thickness measurement, and gonioscopic, biomicroscopic, and funduscopy examination. Paired-samples *t* test was used. A *p* value of <0.05 was taken as significant.*

RESULTS. *The mean duration of follow-up was 14.6 months (SD 5.8). At 9 months, mean IOP was 17.0 (SD 4), the mean IOP reduction was 13.2 mmHg (SD 5.86). At 9 months post-surgery, the complete success rate was 75%. Qualified success was achieved in 100% of patients. At 9 months, the mean number of antiglaucoma medications was 0.58 (SD 1.24) (*p*<0.05). Visual acuity improved by a mean value of 2.8 lines. Average RNFL thickness did not change significantly during the follow-up period (*p*=0.781).*

CONCLUSIONS. *Two-site bimanual MICS-VC-DS appears to be an effective and safe procedure with quick visual rehabilitation, acceptable mid-term IOP control, and the advantage of having fewer complications. (Eur J Ophthalmol 2009; 19: 384-92)*

KEY WORDS. *Cataract surgery, Glaucoma surgery, Viscocanalostomy*

Accepted: September 25, 2008

INTRODUCTION

The association of glaucoma with cataract has become more frequent because of aging populations and the increased risk of cataract development in the patient with glaucoma. As a result, cataract and glaucoma are common conditions that often are diagnosed in the same patient. There is discussion about the handling of cases with coexisting cataract and glaucoma. When glaucoma and cataract coexist, it is logical to think of a combined surgical procedure, to reduce the surgical trauma induced by two surgical procedures and to facilitate faster visual and

functional recovery. For this reason, the trend in current surgical technique is to perform a combined procedure for both pathologic conditions.

The management of cataract in patients with glaucoma has been continuously changing over the past decade. Several different techniques for treating both diseases have been presented. Recently rapidly advancing phacoemulsification techniques, including small incisions and foldable lenses implanted in the bag, as well as improvements in filtering surgery, facilitate safer and more efficient combined surgery.

Phacotrabeculectomy combined with mitomycin C

achieves the best intraocular pressure (IOP) lowering of all types of combined cataract and glaucoma surgery currently possible (1, 2) but is associated with potentially sight-threatening complications (3). Nonpenetrating glaucoma surgery (NPGS) is popular in a number of countries because of its perceived superior safety profile to mitomycin-C trabeculectomy. NPGS procedures are alternatives to trabeculectomy with the advantage of minimizing the risk of postoperative complications related to hypotony. In NPGS, the anterior chamber is not open so that complications related to full-thickness sclerostomy are mainly avoided. The two major variations of NPGS are nonpenetrating viscocanalostomy (Vc) and deep sclerectomy (Ds) with or without external trabeculectomy. The goal of these procedures is to reduce IOP by enhancing the natural aqueous outflow passages while reducing outflow resistance.

The aim of the current study was to evaluate the safety and effectiveness of a new technique, two-site bimanual microincisional cataract surgery combined with viscocanalostomy plus deeper sclerectomy (two-site bimanual MICS-VC-DS), in patients referred to our eye clinic with cataract and glaucoma. We report the results of a consecutive series of patients.

METHODS

From December 2005 to October 2007, a consecutive series of 12 patients (12 eyes) with uncontrolled POAG and cataract underwent two-site bimanual MICS-VC-DS. Possible alternatives, beneficial effects, and potential complications of the surgical procedure were explained in detail to all patients. Fully informed consent was obtained from each patient and each case has been studied in a prospective manner. Patients with angle-closure glaucoma, previous glaucoma surgery, posttraumatic, uveitic, and dysgenetic or neovascular glaucoma were not considered for this study.

The inclusion criteria were primary open-angle glaucoma; Goldmann applanation tonometry showing IOP > 22 mmHg in at least two different examinations; gonioscopy showing an open angle; a glaucomatous optic neuropathy, that is, localized or generalized narrowing of the neuroretinal rim, cup/disc asymmetry >0.2, or disc hemorrhage and at least two reliable (4) SITA Standard Humphrey 24-2 abnormal visual fields; receiving maximal tolerable antiglaucomatous therapy; and cataract that is

visually significant. No antimetabolites, collagen or gel implants were used in any eye in this study.

Prior to surgical intervention, all patients underwent a baseline ophthalmic examination that included measurement of best-corrected visual acuity, biomicroscopy, gonioscopy, and Goldmann applanation tonometry.

Surgical procedure

All eyes underwent two-site bimanual MICS-VC-DS, performed by the same surgeon (M.B.). Two clear-corneal side port incisions were made at 10 o'clock and 2 o'clock. Two clear corneal unipolar stab incisions of 1.4-mm width or less were created. The width of the incision is made slightly larger than both the phaco needle and the irrigating chopper to avoid tension on the incision and may allow a slight egress of fluid around the instruments. Viscoelastic is injected into the anterior chamber. A continuous curvilinear capsulorhexis 5.0–6.0 mm in diameter was created to achieve anterior capsulotomy. Hydrodissection was followed by phacoemulsification of the nucleus, with subsequent aspiration of the remaining cortical material. One of the stab incisions may be enlarged for intraocular lens insertion. Then an acrylic intraocular lens was implanted in the capsular bag. After the injection of the intraocular lens into the capsular bag, residual viscoelastic is removed, and both stabs are stromally hydrated.

Deep sclerectomy was performed in the superior quadrant and was started with the creation of a fornix-based conjunctival flap. After the dissection of a superficial limbus-based quadrangular 5 x 5-mm scleral flap brought forward as far as 1.5 mm into clear cornea, a second limbus-based 4 x 4 mm quadrangular scleral flap was then dissected delicately under the superficial one, leaving a thin layer of deep sclera over the choroid posteriorly, at the depth that allows the visualization of the darker color of the ciliary body below the scleral fibers. The removal of the deep scleral flap leads to formation of an empty space called subscleral lake, or aqueous decompression space (5), where the aqueous humor will be collected before its drainage. External wall of Schlemm's canal (SC) was deroofed during the extension of the deep scleral flap to its limbal edges (Fig. 1). The dissection is then carried anteriorly until only a layer of the Descemet membrane separates the anterior chamber from the outside and acts as an outflow resistance site (6).

We used deeper sclerectomy rather than external trabeculectomy (7-9) for the filtering portion of the proce-

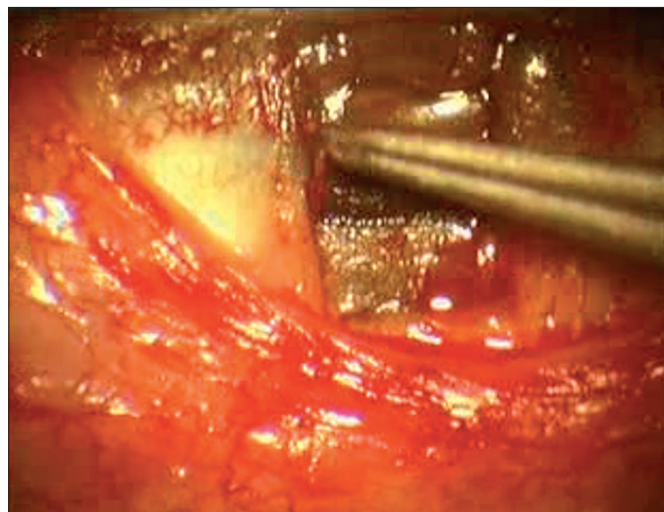


Fig. 1 - Opening the external wall of Schlemm's canal during the extension of the deep scleral flap to its limbal edges.

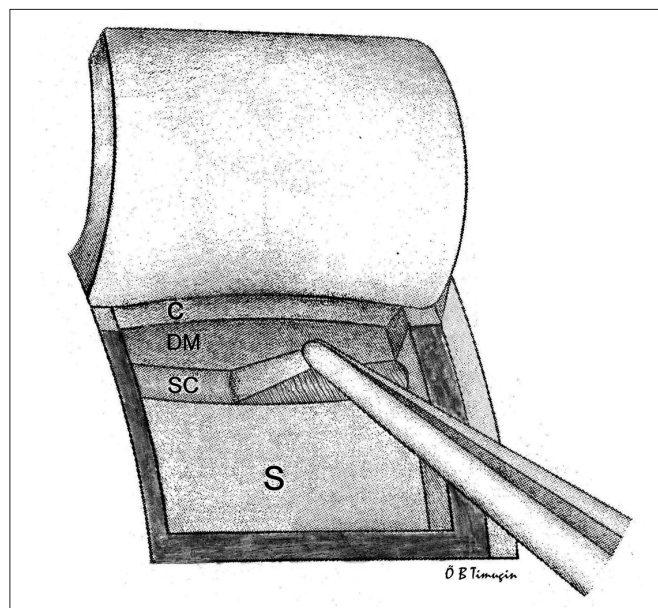


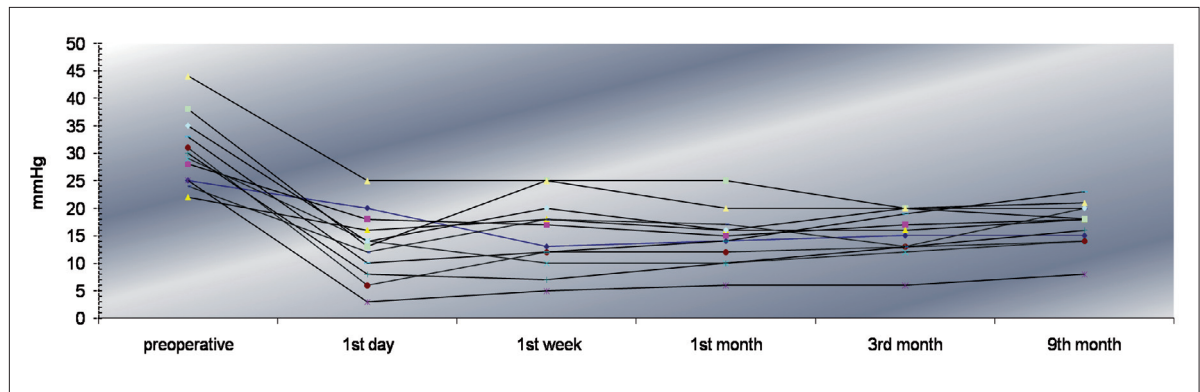
Fig. 2 - Deeper sclerectomy. Selective removal of the external part of the trabecular meshwork, the inner wall of SC, and the adjacent trabecular meshwork layers, while leaving intact the innermost trabecular meshwork layers, requires careful scraping of the bed of SC with a forceps. C = cornea; S = sclera; SC = Schlemm's canal; DM = Descemet membrane.

cedure, the selective removal of the external part the trabecular meshwork, the inner wall of SC, and the adjacent trabecular meshwork layers, while leaving intact the innermost trabecular meshwork layers requires careful scraping of the bed of SC with a forceps (Fig. 2). This leads to the removal of a homogenous external trabecular membrane in one coherent plane that allows aqueous humor to egress through the remaining inner trabecular layers (9, 10). Then after probing the artificial orifices by a thin cannula, SC was delicately filled with high-viscosity sodium hyaluronate (Healon GV) to enlarge the canal. Contrary to the standard viscocanalostomy procedure (11) a paracentesis puncture, watertight suturing of the first scleral flap, and viscoelastic injection into the sub-scleral lake were not performed. Superficial quadrangular scleral flap was secured with two loose nylon 10-0 sutures. The conjunctiva was closed with a continuous 9.0 polyglactin suture. Dexamethasone and gentamicin were applied subconjunctivally. During the first 7 days after surgery, we performed bleb massage when IOP was over 18 mmHg, and then asked patients and their relatives to perform bleb massage at home three times a day. The standard postoperative regimen consisted of topical lomefloxacin 0.3% twice and fluorometholone (1 mg/mL) eight times daily. The steroid dose was continuously reduced over a period of at least 4 weeks. Postoperatively all patients were again evaluated regularly. Postoperative evaluation included visual acuity (VA); IOP measurement

by Goldmann applanation tonometry; the presence of any filtering bleb; gonioscopic, biomicroscopic, and funduscopic examination; and standard optical coherence tomography (OCT) average RNFL thickness measurement. These examinations, except gonioscopy and OCT average RNFL thickness, were performed at each postoperative visit at day 1, day 7, 1 month, 3 months, and 9 months. All examinations were conducted by an ophthalmologist (O.B.T.) on the same surgical team. Peripapillary RNFL thickness was measured on standard OCT (Stratus OCT; Carl Zeiss Meditec, Dublin, CA, USA) using the fast RNFL thickness protocol. Postoperative OCT average RNFL thickness measurements have been tested at first and ninth months. To aid comparison with the results of other studies, we have utilized the complete success criteria as IOP <22 mmHg without any additional glaucoma surgery or medication, whereas qualified success was defined as IOP <22 mmHg with additional antiglaucoma medications. Failure was defined as an IOP >21 mmHg even with medication.

Statistical analysis was performed using the SPSS version 13.0 for Windows commercial statistical software package (SPSS, Inc, Chicago, IL, USA). Paired samples *t* test was used. A *p* value of <0.05 was taken as significant.

Fig. 3 - Pre- and postoperative intraocular pressure readings in 12 operated eyes.



RESULTS

We studied 12 eyes of 12 consecutive patients who underwent two-site bimanual MICS-VC-ET between May 2005 and April 2007, with minimum follow-up periods of 9 months. Twelve patients, seven men and five women, completed the study. Their mean age was 62.9 years (SD 9.4). The mean duration of follow-up was 14.6 months (SD 5.8) (range 9–24 months). All patients used glaucoma medications before surgery. One eye (8.3%) was treated with one drug, 5 eyes (41.6%) with three drugs, 6 eyes (50%) with four drugs. Mean preoperative IOP was 30.3 mmHg (SD 6) for all patients enrolled. At the first day postsurgery, mean IOP was 13.25 mmHg (SD 6.1). At the first week postsurgery, mean IOP was 15.16 mmHg (SD 6.4). At the end of the first month, mean IOP was 14.6 mmHg (SD 5.0). At the ninth month, mean IOP was 17.0 (SD 4), and mean IOP reduction was 13.2 mmHg (SD 5.8) (Tab. I, Fig. 3). At 9 months postsurgery the complete suc-

cess rate, defined as IOP <22 mmHg without medication, was 75%. Qualified success, defined as IOP <22 mmHg with at least one antiglaucomatous medication, was achieved in 100% of patients. When surgical complete success was defined as greater than or equal to 30% IOP reduction from preoperative level without medical or additional surgical treatment, complete surgical success rate was 83.3%. At the last follow-up visit, intraocular pressure was below 21 mmHg in 91.6% (n=11) of all cases (Fig. 1). Postoperatively, the mean number of antiglaucoma medications was significantly reduced. At 9 months, the mean number of antiglaucoma medications was 0.58 (SD 1.24) (p<0.05). At the last follow-up, 3 eyes (25%) were on an average of 2.3 antiglaucoma medications. VA improved by a mean value of 2.8 lines. Mean VA increased significantly (p=0.02). Twelve eyes (100%) showed an improvement in visual acuity by at least two Snellen lines. Average RNFL thickness was 69.16 (SD: 13.9) and 70.75 (SD: 13.78), respectively, at postoperative

TABLE I - POSTOPERATIVE COURSE WITH REGARD TO MEAN INTRAOCULAR PRESSURE (IOP), MEAN NUMBER OF ANTIGLAUCOMA MEDICATIONS, AND AVERAGE STRATUS OCT RNFL THICKNESS

Bimanual microincisional phaco-viscocanalostomy plus deeper sclerectomy						
	Mean IOP (mmHg)		Mean number of medications		Average RNFL thickness (OCT)	
	SD	p	SD	p	SD	p
Preoperative	29.3 (5.0)	NA	3.41 (0.6)	NA	NA	NA
Postoperative first day	13.2 (6.1)	<0.05				
Postoperative first week	15.1 (6.4)	<0.05	0.08 (0.3)	<0.05	NA	
Follow-up 1 month	14.6 (5.0)	<0.05	0.08 (0.3)	<0.05	69.2 (13.9)	
Follow-up 3 months	15.3 (4.2)	<0.05	0.33 (0.6)	<0.05	NA	
Follow-up 9 months	17.0 (4.0)	<0.05	0.58 (1.2)	<0.05	70.7 (13.8)	0.781

OCT = optical coherence tomography; RNFL= retinal nerve fiber length; SD = standard deviation; NA = not applicable.

first and ninth month, and did not change significantly during the follow-up period ($p=0.781$).

As a complication of surgery one (8.3%) case had mild hyphema, one (8.3%) case had shallow anterior chamber, and one (8.3%) had hypotony, recovered at the end of the first month. None of these complication required surgical treatment, and all were self-limited. Serious complications such as anterior chamber loss, hypotonic maculopathy, bleb leakage, blebitis/endophthalmitis, perforation, choroidal detachment/hemorrhagia, and detachment/rupture of Descemet membrane were not seen (Tab. II).

DISCUSSION

Both Vc and Ds may be combined with cataract surgery. Although the literature is sparse, there is no evidence of differences in the success rates or postoperative IOP between phacoemulsification (Phaco) combined with either Vc or Ds. Significant lowering of IOP with rapid visual recovery following combined phacoemulsification cataract extraction and Ds were reported (12, 13), and safely combined cataract surgery with both Vc and Ds. Interestingly, contrary to trabeculectomy, NPGS does not appear to have a negative effect on IOP control or low success rates when combined with Phaco cataract extraction. In one study, D'Eliseo et al (14) compared IOP regulation and success rates after combined Phaco and deep sclerectomy with those after deep sclerectomy alone, and reported that the combined group had better mean IOP (13.1 vs 15.2 mmHg) and higher success rates (<21 mmHg without medication) of 90% versus 62%. Our results reported in this paper seem to offer comparable, even better success rate in mean IOP reduction as compared with the study of D'Eliseo et al and the other combined phaco plus Ds and Vc procedures (14-16). We have demonstrated that two-site bimanual MICS-VC-DS achieved similar results with a lower rate of complications and performed equally as well as phaco-Ds or Vc in terms of IOP lowering and visual outcome. However, it is difficult to compare

these procedures because of the numerous surgical variations.

Bimanual microincisional cataract surgery has recently become a procedure of interest among cataract surgeons, and a number of trials have shown its potential as a minimally invasive cataract surgery. There are several advantages to the bimanual phacoemulsification method of cataract extraction. Minimally invasive cataract surgery reduces surgical trauma, making it possible to obtain better results with combined surgery. Theoretically, smaller incisions prevent large changes in pressure within the eye, prevent the loss of viscoelastic, and therefore provide a more stable anterior chamber during the surgery (17). As a result, steps in cataract surgery such as capsulorhexis and hydrodissection become easier to perform and may reduce the risk of capsular rupture (18). In addition, the small corneal incisions heal quickly, induce less postoperative astigmatism, and are theoretically associated with reduced risk of endophthalmitis (18-20). MICS helps minimize wound gap and fluid leakage from the anterior chamber reasonably (21), make it possible for the glaucoma surgery to be performed on desired region and size, to the advantage of the patient and the doctor during the same session.

NPGSies are alternatives to trabeculectomy with the advantage of minimizing the risk of postoperative complications related to hypotony. Theoretically, the frequency of postoperative complications encountered with penetrating procedures should be significantly lowered in NPGS. In NPGS, the anterior chamber is not open so that complications related to full-thickness sclerostomy are mainly avoided. Regarding the success rates and the mean IOP that can be achieved, recent randomized controlled trials have demonstrated a higher efficacy of trabeculectomy compared with Vc and Ds (22, 23). Our results seem to offer comparable success rate in mean IOP reduction as compared with the abovementioned studies. However, it is difficult to compare these procedures because of numerous surgical variations.

Vs is believed to function via enhanced drainage into SC,

TABLE II - COMPLICATIONS

No. eyes	Perforation, %	Hyphema, %	Flat/shallow anterior chamber, %	Hypotony, %	Choroidal detachment, %	Detachment of Descemet membrane, %	Wound leak, %
12	0	8.3	8.3	8.3	0	0	0

and is theoretically not a filtration procedure. The Vs described by Stegmann (11) acts as Ds, but the procedure is completed by the injection of viscoelastic substance in the SC ostia surgically open so that aqueous egress occurs at the level of SC. However, in this modification the scleral flap is tightly sutured. For the standard procedure, the superficial flap is tightly closed, and high-viscosity sodium hyaluronate is then injected underneath the flap to create a reservoir. The aqueous is supposed to reach the aqueous exit channels that are dilated using viscoelastic in SC. It is postulated that due to the first scleral flap is tightly sutured, physiologic aqueous humor drainage may be restored without formation of a filtration bleb and filtration through the trabeculodescemet membrane remains the only possibility for aqueous humor to reach the two surgically created ostia of SC. However, a study reported that injection of viscoelastic in SC resulted not only in dilatation of the canal and associated collectors but also in disruption of the walls of SC and adjacent trabecular layers (24). Thus, the procedure may act as a trabeculotomy. Studies reported that the Descemet membrane is not permeable enough to allow relief of the elevated IOP of glaucoma (25). Aqueous outflow facility is probably also increased by the damage at the level of the inner wall of SC and the adjacent trabecular layers that is likely to occur when unroofing the SC.

Herein it can also be argued that this procedure converts nonpenetrating surgery into a perforating procedure. However, unroofing SC (i.e., removing the outer and inner wall of SC) can cause microperforations allowing the aqueous humor to percolate through a thin membrane with an anterior chamber that remains deep. We know that 75% of the outflow resistance is attributed to the trabecular meshwork, namely in the inner wall of SC and the adjacent trabecular layers (26), whereas one third of the resistance to outflow lies in the outer wall of SC or tissue surrounding it (27-29). Therefore, removing only outer wall of SC was expected to be seen with insufficient aqueous humor filtration. Thus, we presumed that the outflow resistance would decrease by removing the inner wall of SC and the adjacent trabecular layers that we called deeper sclerectomy.

Evidence has been accumulating that cataract surgery results in a long-term reduction in IOP, with values between 1 and 8 mmHg (30-32). The exact mechanism that causes this effect on the IOP is not well understood. Cohen (33) noted that the reason could be related to the size of the incision, the larger incision size creating an unintentional

filtering effect. Our assumption about this effect here somehow resembles Archimedes principle and Pascal's law. The eyeball is filled with fluid, incompressible contents. Lens is fully immersed in this fluid, aqueous humor. Since fluids are incompressible, lens and inner walls of ocular structures are buoyed up by a force equal to the weight of the fluid displaced by the lens volume. Pressure is transmitted undiminished in an enclosed static fluid. By lens removal, this volume pressure relationship may shift to a new balance between sclera-corneal rigidity and intraocular fluid volume.

One main factor in the success of combined cataract and glaucoma surgery is the control of the inflammatory response caused by aggressive surgery. Despite these data supporting combined surgery (34), there is also evidence showing that trabeculectomy performed alone achieves better IOP reduction than combined surgery. Therefore, it is necessary to look for a technique that reduces surgical trauma. There is some evidence of less tissue aggression with MICS than with other techniques. The superiority of Phaco-Trab over ECCE-Trab is well-known (35).

Although the authors did not clarify the mechanisms that would explain IOP differences, the explanation could be that the surgical trauma is higher in the ECCE-Trab and this supposes a greater alteration of the blood-aqueous barrier or an increase of transforming growth factor-Beta (36, 37). This might result in more aggressive wound healing. Another possible mechanism could be the increased trauma to the wound, also by the longer exposition during surgery. Total ultrasonic energy and hydrodynamic flow in the anterior chamber are another main factor in inflammatory reaction. The total fluid volume used during phacoemulsification was different when MICS and conventional phaco were compared (38). Because of new systems, MICS techniques reduce considerably the amount of energy used, and the needle does not increase the temperature (39). We consider that reduction of flow and total ultrasonic energy is essential to obtain the bimanual MICS goal of reducing tissue aggression and inflammation. We performed glaucoma surgery after cataract surgery, so that inflammation secondary to phacoemulsification is minimized. In combined surgeries, tissue aggression and inflammation are greater. It is then recommended to use subconjunctivally anti-inflammatory treatment (dexamethasone) at the end of surgery.

We consider the two-site incision combined surgical technique the preferred choice.

The benefit of separating the two incisions for cataract

surgery and for trabeculectomy has been discussed. However, two randomized controlled trials failed to demonstrate superiority of two-site compared with one-site surgery (40, 41). The conclusion of a recent evidence-based review (1) was that there is weak evidence of a small positive effect of separating the incisions, the magnitude of the effect being 1 to 2 mmHg. There is no evidence forceful enough to demonstrate that one technique is better than the other, although the data lean toward the two-site technique (40, 41).

One of the arguments for combined surgery is the difficulty in evaluating the visual fields of patients affected by both pathologic conditions (42). The cataract affects the sensitivity and reliability of the visual field test which in turn affects the decision to continue medical management or consider surgery (43). We preferred OCT RNFL thickness follow-up for progression of glaucomatous vision loss since reproducibility of RNFL measurements using the Stratus OCT is excellent in glaucomatous eyes and yields comparable measurements (44).

As safety concerns are a significant barrier to earlier surgery in glaucoma, NPGS will have a worthwhile role earlier in the disease process. Trabeculectomy surgery has been shown to be more cost effective than conventional chronic medical therapy (45). Given the high cost of modern glaucoma medications (46), one would expect NPGS to compare favorably with medication in a cost-benefit analysis. Although the IOP reduction did not meet the complete success criteria in all cases, the mean number of glaucoma medications decreased from 3.4 preoperatively to 0.6 postoperatively.

We used two loose sutures for readaptation of the scleral flap and got a relatively high rate of bleb formation (75%). By contrast with our observations, Stegman et al (11) reported formation of a filtering bleb in 5% of eyes after Vc. However, bleb formation is comparable with the results of previous studies, with blebs occurring in up to 60% of eyes after Ds (47, 48). Although other surgeons close scleral flaps with at least three sutures, they also observe bleb formation in up to 50% of eyes after Vc (9).

The results of combined surgeries are not easy to compare because criteria for success differ, length of follow-up varies, surgical techniques are different, and patient composition is not uniform between studies. As this first series were small in number and did not have a control group, it remains difficult to draw definitive conclusions with reference to the long-term success. More prospective, randomized, controlled trials with sufficiently large numbers are needed before general conclusions can be drawn. Two-site bimanual MICS-VC-DS appears to be an effective and safe procedure with fast visual rehabilitation, acceptable mid-term IOP control, and the advantage of having fewer complications.

The authors have no proprietary interest or financial support.

Reprint requests to:
Mehmet Baykara, MD
Department of Ophthalmology
Uludag University Faculty of Medicine
16059 Gorukle, Bursa, Turkey
mehmetbaykara@hotmail.com
obtimucin@mynet.com

REFERENCES

1. Jampel HD, Friedman DS, Lubomski LH, et al. Effect of technique on intraocular pressure after combined cataract and glaucoma surgery: an evidence based review. *Ophthalmology* 2002; 109: 2215-24; quiz: 2225, 2231.
2. Casson RJ, Salmon JF. Combined surgery in the treatment of patients with cataract and primary open-angle glaucoma. *J Cataract Refract Surg* 2001; 27: 1854-63.
3. Cohen JS, Greff LJ, Novack GD, et al. A placebo-controlled, double-masked evaluation of mitomycin C in combined glaucoma and cataract procedures. *Ophthalmology* 1996; 103: 1934-42.
4. Anderson DR, Patella VM. *Automated Static Perimetry*. 2nd ed. St. Louis, MO: Year Book Mosby; 1999: 10-35.
5. Sourdille P, Santiago PY, Villain F, et al. Reticulated hyaluronic acid implant in nonperforating trabecular surgery. *J Cataract Refract Surg* 1999; 25: 332-9.
6. Rossier A, Uffer S, Mermoud A. Aqueous dynamics in experimental ab externo trabeculectomy. *Ophthalmic Res* 2000; 32: 165-71.

7. Zimmerman TJ, Koener KS, Ford VJ, et al. Trabeculectomy vs. nonpenetrating trabeculectomy: a retrospective study of two procedures in phakic patients with glaucoma. *Ophthalmic Surg* 1984; 15: 734-9.
8. Tanihara H, Negi A, Akimoto M, et al. Surgical effects of trabeculotomy ab externo on adults eyes with primary open angle glaucoma and pseudoexfoliation syndrome. *Arch Ophthalmol* 1993; 111: 1653-61.
9. Mermoud A. Sinusotomy and deep sclerectomy. *Eye* 2000; 14: 531-5.
10. Mermoud A, Schnyder CC. Nonpenetrating filtering surgery in glaucoma. *Curr Opin Ophthalmol* 2000; 11: 151-7.
11. Stegmann R, Pienaar A, Miller D. Viscocanalostomy for open-angle glaucoma in black African patients. *J Cataract Refract Surg* 1999; 25: 316-22.
12. Gianoli F, Schnyder CC, Bovey E, Mermoud A. Combined surgery for cataract and glaucoma: phacoemulsification and deep sclerectomy compared with phacoemulsification and trabeculectomy. *J Cataract Refract Surg* 1999; 25: 340-6.
13. Wishart PK, Wishart MS, Porooshani H. Viscocanalostomy and deep sclerectomy for the surgical treatment of glaucoma: a long-term follow-up. *Acta Ophthalmol Scand* 2003; 81: 343-8.
14. D'Eliseo D, Pastena B, Longanesi L, et al. Comparison of deep sclerectomy with implant and combined glaucoma surgery. *Ophthalmologica* 2003; 217: 208-11.
15. Lüke C, Dietlein TS, Lüke M, Konen W, Krieglstein GK. Phaco-trabeculectomy combined with deep sclerectomy, a new technique in combined cataract and glaucoma surgery: complication profile. *Acta Ophthalmol Scand* 2007; 85: 143.
16. Uretmen O, Ates H, Guven S, et al. Comparison of outcomes of viscocanalostomy and phacoviscocanalostomy. *Can J Ophthalmol* 2003; 38: 580-6.
17. Soscia W, Howard JG, Olson RJ. Bimanual phacoemulsification through 2 stab incisions: a wound temperature study. *J Cataract Refract Surg* 2002; 28: 1039-43.
18. Mamalis N. Is smaller better? *J Cataract Refract Surg* 2003; 29: 1049-50.
19. Tsuneoka H, Shiba T, Takahashi Y. Feasibility of ultrasound cataract surgery with a 1.4 mm incision. *J Cataract Refract Surg* 2001; 27: 934-40.
20. Tsuneoka H, Shiba T, Takahashi Y. Ultrasonic phacoemulsification using a 1.4 mm incision: clinical results. *J Cataract Refract Surg* 2002; 28: 81-6.
21. Baykara M, Ercan I, Ozcetin H. Microincisional cataract surgery (MICS) with pulse and burst modes. *Eur J Ophthalmol* 2006; 16: 804-8.
22. Luke C, Dietlein TS, Jacobi PC, et al. A prospective randomized trial of viscocanalostomy versus trabeculectomy in open-angle glaucoma: a 1-year follow up study. *J Glaucoma* 2002; 11: 294-9.
23. Cillino S, Di Pace F, Casuccio A, et al. Deep sclerectomy versus punch trabeculectomy with and without phacoemulsification: a randomised clinical trial. *J Glaucoma* 2004; 13: 500-6.
24. Smit BA, Johnstone MA. Effects of viscocanalostomy on the histology of Schlemm's canal in primate eyes. *Ophthalmology* 2002; 109: 786-92.
25. Spiegel D, Scheffthaler M, Kobuch K. Outflow facilities through Descemet's membrane in rabbits. *Graefes Arch Clin Exp Ophthalmol* 2002; 240: 111-3.
26. Mäepea O, Bill A. Pressures in the juxtacanalicular tissue and Schlemm's canal in monkeys. *Exp Eye Res* 1992; 54: 879-83.
27. Seiler T, Wollensak J. The resistance of the trabecular meshwork to aqueous humor outflow. *Graefes Arch Clin Exp Ophthalmol* 1985; 223: 88-91.
28. Johnson MC, Kamm RD. The role of Schlemm's canal in aqueous outflow from the human eye. *Invest Ophthalmol Vis Sci* 1983; 24: 320-5.
29. Mäepea O, Bill A. The pressures in the episcleral veins, Schlemm's canal, and the trabecular meshwork in monkeys: effects of changes in intraocular pressure. *Exp Eye Res* 1989; 49: 645-63.
30. Hayashi K, Hayashi H, Nakao F, et al. Effect of cataract surgery on intraocular pressure control in glaucoma patients. *J Cataract Refract Surg* 2001; 27: 1779-86.
31. Pohjalainen T, Vesti E, Uusitalo RJ, et al. Phacoemulsification and intraocular lens implantation in eyes with open-angle glaucoma. *Acta Ophthalmol Scand* 2001; 79: 313-6.
32. Shingleton BJ, Gamell LS, O'Donoghue MW, et al. Long-term changes in intraocular pressure after clear corneal phacoemulsification: normal patients versus glaucoma suspect and glaucoma patients. *J Cataract Refract Surg* 1999; 25: 885-90.
33. Cohen JS. Combined cataract implant and filtering surgery with 5-fluorouracil. *Ophthalmic Surg* 1990; 21: 181-6.
34. Friedman DS, Jampel HD, Lubomski LH, et al. Surgical strategies for coexisting glaucoma and cataract: an evidence-based update. *Ophthalmology* 2002; 109: 1902-13.
35. Wishart PK, Austin MW. Combined cataract extraction and trabeculectomy: phacoemulsification compared with extracapsular technique. *Ophthalmic Surg* 1993; 24: 814-21.
36. Siriwardena D, Kotecha A, Minassian D, et al. Anterior chamber flare after trabeculectomy and after phacoemulsification. *Br J Ophthalmol* 2000; 84: 1056-57.
37. Vass C, Menapace R. Surgical strategies with combined cataract and glaucoma. *Curr Opin Ophthalmol* 2004; 15: 61-6.
38. Millá E, Vergés C, Ciprés M. Corneal endothelium evaluation after phacoemulsification with continuous anterior chamber infusion. *Cornea* 2005; 24: 278-82.

39. Soscia W, Howard JG, Olson RJ. Microphacoemulsification with Whitestar: a wound temperature study. *J Ophthalmol* 2002; 28: 1044-6.
40. Borggreffe J, Lieb W, Grehn F. A prospective randomized comparison of two techniques of combined cataract-glaucoma surgery. *Graefes Arch Clin Exp Ophthalmol* 1999; 237: 887-92.
41. Wyse T, Meyer M, Ruderman JM, et al. Combined trabeculectomy and phacoemulsification: a one-site vs a two-site approach. *Am J Ophthalmol* 1998; 125: 334-9.
42. AGIS Investigators. The advanced glaucoma intervention study: 6. Effects of cataract on visual field and visual acuity. *Arch Ophthalmol* 2000; 118: 1639-52.
43. Sample PA, Johnson CA, Haegerstrom-Portnoy G, et al. Optimum parameters for short-wavelength automated perimetry. *J Glaucoma* 1996; 5: 375-83.
44. Budenz DL, Chang RT, Huang X, Knighton RW, Tielsch JM. Reproducibility of retinal nerve fiber thickness measurements using the Stratus OCT in normal and glaucomatous eyes. *Invest Ophthalmol Vis Sci* 2005; 46: 2440-3.
45. Ainsworth JR, Jay JL. Cost analysis of early trabeculectomy versus conventional management in primary open angle glaucoma. *Eye* 1991; 5: 322-8.
46. Bateman DN, Clark R, Azuaro Blanco A, et al. The effects of new topical treatments on the management of glaucoma in Scotland: an examination of ophthalmological healthcare. *Br J Ophthalmol* 2002; 86: 551-4.
47. Marchini G, Marraffa M, Brunelli C, Morbio R, Bonomi L. Ultrasound biomicroscopy and intraocular pressure-lowering mechanisms of deep sclerectomy with reticulated hyaluronic acid implant. *J Cataract Refract Surg* 2001; 27: 507-17.
48. Sanchez E, Schnyder CC, Sickenberg M, et al. Deep sclerectomy: results with and without collagen implant. *Int Ophthalmol* 1997; 20: 157-62.