

## Abortion due to *Streptococcus equi* subspecies *zooepidemicus* in a Mare

A. Levent KOCABIYIK

Department of Microbiology, Faculty of Veterinary Medicine, Uludağ University, Bursa - TURKEY  
e-mail: klevent@uludag.edu.tr

Gürsel SÖNMEZ

Department of Pathology, Faculty of Veterinary Medicine, Uludağ University, Bursa - TURKEY

Mihriban ÜLGEN

Department of Microbiology, Faculty of Veterinary Medicine, Uludağ University, Bursa - TURKEY

Cüneyt ÖZAKIN

Department of Microbiology and Infectious Diseases, Faculty of Medicine, Uludağ University, Bursa - TURKEY

Esra KOCAKAYA

Department of Microbiology, Faculty of Veterinary Medicine, Uludağ University, Bursa - TURKEY

Aylin ALASONYALILAR

Department of Pathology, Faculty of Veterinary Medicine, Uludağ University, Bursa - TURKEY

Received: 17.06.2004

**Abstract:** The organs of an aborted equine fetus were examined histopathologically and microbiologically. Diffuse, mild cellular infiltration of neutrophils, lymphocytes and plasma cells was observed in the lamina propria of the intestine. In addition, bacterial colonies were seen in the intestinal content, wall of intestine and liver. *Streptococcus equi* subsp. *zooepidemicus* was isolated in pure culture from all organs. This is the first report of the isolation of *S. equi* subsp. *zooepidemicus* from an aborted equine fetus in Turkey.

**Key Words:** Horse, fetus, abortion, *Streptococcus equi* subspecies *zooepidemicus*

### Bir Kısırakta *Streptococcus equi* subspecies *zooepidemicus*'dan Kaynaklanan Abort

**Özet:** Bu çalışmada, atık bir at fötüsüne ait organlar histopatolojik ve mikrobiyolojik yönden incelendi. Barsağın lamina propriasında diffuz, hafif şiddette nötrofil, lenfosit ve plazma hücresi infiltrasyonu gözlemlendi. Ayrıca, bağırsak içeriği, bağırsak duvarı ve karaciğerde bakteri kümelerine rastlandı. Tüm organlardan *Streptococcus equi* subsp. *zooepidemicus* saf kültür halinde izole edildi. Bu, Türkiye'de atık at fötüsünden *S. equi* subsp. *zooepidemicus* izolasyonuna dair ilk rapordur.

**Anahtar Sözcükler:** At, fötüs, abort, *Streptococcus equi* subspecies *zooepidemicus*

### Introduction

Abortion in horses may result from a variety of causes divided into two categories: infectious and non-infectious. Infectious agents such as bacteria, viruses or fungi may attack the fetus or its membranes, resulting in fetal death and its expulsion. Non-infectious agents such as development of twins, torsion of umbilical cord or congenital anomalies may also result in death of the fetus and abortion (1,2).

Several species of bacteria have been incriminated as causative agents of equine abortion. *Streptococcus equi* subsp. *zooepidemicus* is one of the most frequent causes of infectious abortion in mares (1,2).

The present paper reports the first case of abortion caused by *S. equi* subsp. *zooepidemicus* in a mare in Turkey.

### Case History

An equine fetus aborted in the fifth month of pregnancy in a stud farm was submitted to the Veterinary Faculty, Uludağ University, Bursa, Turkey for diagnostic evaluation. The fetus in fresh postmortem condition was a male. The fetus was necropsied and the organs were examined macroscopically.

Tissue samples were taken from the brain, lung, heart, liver, spleen, kidney, stomach, intestine, and testis for histopathological examination. The samples were fixed in 10% formalin and embedded in paraffin wax, sectioned at 5-6 µm and mounted on glass slides. The sections were stained with hematoxylin and eosin (HE), and examined by a light microscope. For microbiological examination, samples were taken from the brain, lung, liver, spleen, kidney, stomach, and testis. Smears of tissues and fetal stomach content were stained with Gram and modified Ziehl-Neelsen methods.

Samples of tissues and stomach content were inoculated onto Blood Agar (Oxoid CM271) with 7% sheep blood, MacConkey Agar (Oxoid CM115), and special culture mediums for other known bacterial causes of abortion in mares, and incubated at 37 °C until colonial growth was seen under aerobic and microaerobic conditions. The plates were discarded after the seventh day if no colonial growth was seen. In addition, the samples were inoculated onto Sabouraud Dextrose Agar for fungi (Oxoid CM41) and incubated at 25 °C and 37 °C in the dark for a minimum of three weeks, and examined weekly for evidence of fungal growth.

The isolate was identified on the basis of colonial and cellular morphology, Gram staining, and biochemical characteristics using standard procedures (3) and BBL™ Crystal™ Gram-Positive ID System (BD Diagnostic Systems, Sparks, MD, USA). The CAMP test with *Staphylococcus aureus* was also performed according to the recommendations of Quinn et al. (3).

Susceptibility of the isolate to antimicrobial agents such as penicillin, ampicillin, amoxycillin/clavulanic acid, trimethoprim/sulphamethoxazole, streptomycin, neomycin, kanamycin, gentamicin, erythromycin, oxytetracycline, chloramphenicol, bacitracin, and enrofloxacin was determined by Kirby Bauer disk diffusion (4) on Mueller-Hinton Agar (Oxoid CM337) with 7% sheep blood. The plates were incubated at 37 °C for a minimum of 18 hours under microaerobic conditions.

### Results and Discussion

At necropsy, no macroscopic lesion was detected in the organs. In the histopathological examination of the intestine, diffuse, mild cellular infiltration of neutrophils, lymphocytes, and plasma cells was observed in the lamina propria. There were necrosis and desquamation of epithelial cells of intestinal villi and crypts. Dark basophilic cocci, representing bacterial colonies were present in the intestinal luminal content and also as scattered in the lamina propria and submucosa (Figure 1). Similar colonies of bacteria or bacterial emboli without inflammatory reaction were also observed in some blood vessels of intestinal wall, sinusoids in the liver, and in mesentery (Figure 2). Blood vessels in the portal areas

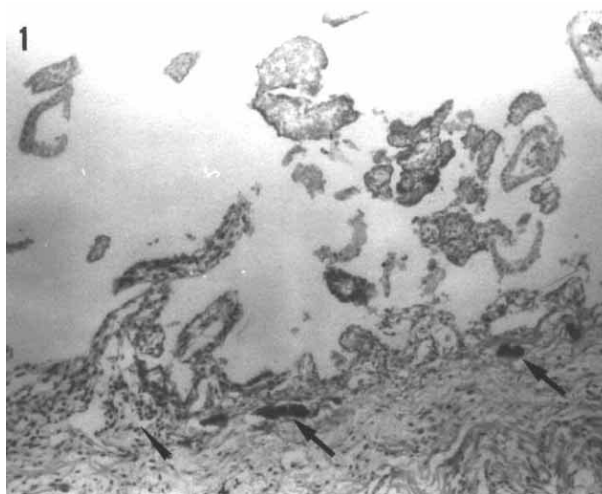


Figure 1. Bacterial colonies (arrows) and mild cellular infiltrates (arrow head) in the lamina propria of the intestine. HE x 200.

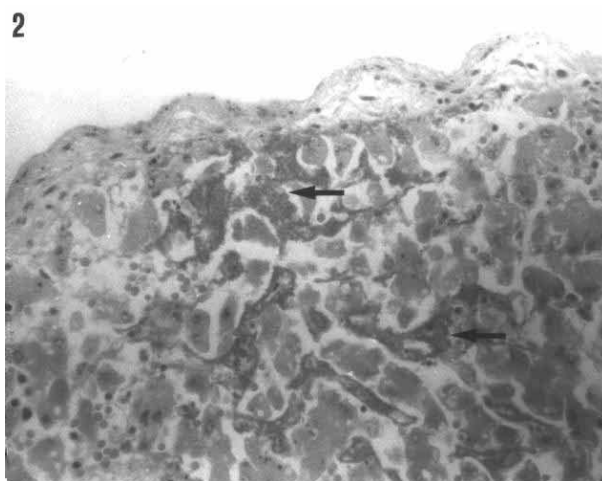


Figure 2. Bacterial emboli (arrows) without inflammatory reaction in the sinusoids of the liver. HE x 400.

and sinusoids were hyperemic, and a few foci of hemorrhage were seen in the liver and testis. No histopathological finding was observed in the other organs examined.

According to the report of Kennedy and Miller (5), bacterial fetal infections can occur via hematogenous or transcervical route. Transcervical infection is considered the main route of fetoplacental infection (1). *S. equi* subsp. *zoepidemicus*, normally resident in the lower genital tract of mares, can cause opportunistic infection by transcervical route, resulting in placentitis and abortion (1,2,6). In the present case, the placenta could not be examined as it was not submitted for diagnostic evaluation. According to the same report of Kennedy and Miller (5), the fetus swallows amniotic fluid beginning at a very early age, and bacteria can be seen in the intestinal luminal content of the aborted fetus. Histopathological findings in the intestine of the aborted fetus suggested that placentitis resulting in abortion might be present in the mare.

Microscopic examination of Gram stain smears prepared from the tissues and stomach content revealed large numbers of Gram-positive cocci. No acid-alcohol fast organisms were observed on the smears stained with modified Ziehl-Neelsen.

Colonial growth was seen only on blood agar inoculated with all tissues and stomach content after 18-24 hours' incubation. The  $\beta$ -hemolytic colonies were translucent and approximately 1 mm in diameter. Gram-positive catalase-negative cocci arranged in chains were identified as streptococci. The isolate was identified as *S. equi* subsp. *zoepidemicus* after negative aesculin and

sodium hippurate hydrolysis reactions; fermentation of lactose, salicin, and sorbitol but not mannitol, raffinose, and trehalose; negative CAMP reaction and several other biochemical characteristics determined using BBL™ Crystal™ Gram-Positive ID System.

In antimicrobial susceptibility testing, the isolate was found susceptible to penicillin, ampicillin, amoxicillin/clavulanic acid, trimethoprim/sulphamethoxazole, gentamicin, erythromycin, oxytetracycline, chloramphenicol, bacitracin, and enrofloxacin.

There have been several comprehensive reviews of the causes of equine abortion in the United States (1,2), the United Kingdom (6), Egypt (7), and New Zealand (8). In all reviews, *S. equi* subsp. *zoepidemicus* has been indicated as the most frequent bacteria isolated from the aborted equine fetuses. Although it was reported to be isolated from genital organs of normal and subfertile mares (9), no investigation has reported isolation from an aborted equine fetus in Turkey. In a single study carried out to determine the causative bacterial agents of equine abortions in Turkey, several species such as *Escherichia coli*, *Staphylococcus aureus*, *Rhodococcus equi*, *Corynebacterium pseudotuberculosis*, and *Pseudomonas* spp., but not *S. equi* subsp. *zoepidemicus*, were reported to be isolated from the aborted equine fetuses (10).

To our knowledge, this is the first report of the isolation of *S. equi* subsp. *zoepidemicus* from an aborted equine fetus in Turkey. In conclusion, *S. equi* subsp. *zoepidemicus* should not be underestimated in equine abortion episodes.

## References

- Giles, R.C., Donahue, J.M., Hong, C.B., Tuttle, P.A., Petrites-Murphy, M.B., Poonacha, K.B., Roberts, A.W., Tramontin, R.R., Smith, B., Swerczek, T.W.: Causes of abortion, stillbirth, and perinatal death in horses: 3,527 cases (1986-1991). *J. Am. Vet. Med. Assoc.*, 1993; 203: 1170-1175.
- Hong, C.B., Donahue, J.M., Giles, R.C. Jr., Petrites-Murphy, M.B., Poonacha, K.B., Roberts, A.W., Smith, B.J., Tramontin, R.R., Tuttle, P.A., Swerczek, T.W.: Equine abortion and stillbirth in central Kentucky during 1988 and 1989 foaling seasons. *J. Vet. Diagn. Invest.*, 1993; 5: 560-566.
- Quinn, P.J., Carter, M.E., Markey, B., Carter, G.R.: The streptococci and related cocci. In: Quinn, P.J., Carter, M.E., Markey, B., Carter, G.R., Eds. *Clinical Veterinary Microbiology*. Mosby, Edinburgh. 2000; 127-136.
- National Committee for Clinical Laboratory Standards: Performance standards for antimicrobial disk susceptibility tests. Approved Standard M2-A7. National Committee for Clinical Laboratory Standards, Wayne, Pennsylvania. 2000.
- Kennedy, P.C., Miller, R.B.: The female genital system. In: Jubb, K.V.F., Kennedy, P.C., Palmer, N., Eds. *Pathology of Domestic Animals*. 4th ed., Vol. 3, Acad. Press, San Diego. 1993; 349-470.
- Smith, K.C., Blunden, A.S., Whitwell, K.E., Dunn, K.A., Wales, A.D.: A survey of equine abortion, stillbirth and neonatal death in the UK from 1988 to 1997. *Equine Vet. J.*, 2003; 35: 496-501.
- Dawlat, A., Orman, R., Essam, I., Ahmed, M.: Abortion and stillbirth in Arabian mare: clinical, etiological and pathological studies in Arabian mare. *Assiut Vet. Med. J.*, 2002; 47: 279-295.

8. Julian, A.F.: Equine abortions in New Zealand between 1974 and 1990. *Surveill. Wellington*, 1992; 19: 24-25.
9. Erdeğer, J., Akan, M., Dakman, A., Altay, G., Vural, R., Çelebi, M.: Kısrakların genital organlarından izole edilen  $\beta$ -hemolitik streptokok'ların identifikasyonu ve sero gruplandırılması. *Ankara Üniv. Vet. Fak. Derg.*, 1999; 46: 69-76.
10. Ak, S., Hasöksüz, M., Turan, N., Kılıçarslan, N.R.: Bacteria isolated from aborted fetuses of mares. *III Natl. Cong. Vet. Microbiol., Bursa*. 1998; 76.