

Vascular Ring Anomaly Associated with Right Aortic Arch in a German Shepherd Dog

Ebru YALÇIN^{1,*}, Nureddin ÇELİMLİ², İ. Taci CANGÜL³, Ahmet AKKOÇ³, Zeki YILMAZ¹

¹Department of Internal Medicine, Faculty of Veterinary Medicine, Uludağ University, Bursa - TURKEY

²Department of Surgery, Faculty of Veterinary Medicine, Uludağ University, Bursa - TURKEY

³Department of Pathology, Faculty of Veterinary Medicine, Uludağ University, Bursa - TURKEY

Received: 24.12.2007

Abstract: A 12-week-old, intact, male German shepherd dog was presented with a history of regurgitation since weaning to solid food. The dog was emaciated, and the cervical esophagus of the animal was palpable as a flaccid and air-filled cavity. Contrast radiography of esophagus revealed contrast material accumulation in the thoracic esophagus craniodorsal to the heart. A diagnosis of vascular ring anomaly was made and surgical correction of the defect was decided. The dog died during the preoperative period despite supportive treatment in intensive care unit. Necropsy findings confirmed a diagnosis of persistent right aortic arch.

Key Words: Vascular ring anomaly, congenital, aortic arch, dog

Bir Alman Çoban Köpeğinde Sağ Aortik Kemer ile İlişkili Vasküler Ring Anomalisi

Özet: Sütten kesildikten sonra katı gıdaları regürjite eden 12 haftalık, erkek bir Alman çoban köpeği değerlendirildi. Köpek zayıf ve olması gereken kilonun altındaydı. Servikal ösefagus gevşek ve hava ile dolu olarak palpe edildi. Ösefagusun radyografisinde kalbin kraniodorsalinde, torasik bölgede kontrast madde ile dolu ösefagus belirlendi. Bu gözlemler temelinde, vasküler ring anomalisi tanımlandı ve operasyona karar verildi. Operasyon hazırlıkları sırasında destek tedavisine rağmen köpek yoğun bakımda öldü. Nekropsi bulguları kalıcı sağ aortik kemer tanısını doğruladı.

Anahtar Sözcükler: Vasküler ring anomalisi, konjenital, aortik kemer, köpek

Introduction

Vascular rings are developmental anomalies of the aortic arches in which the esophagus and the trachea are encircled either completely or partially by vasculature (1). During early fetal life, 6 pairs of aortic arches surround the esophagus and trachea. Normal maturation and selective regression of these structures form the adult vasculature. Abnormal location or development of the aortic arches may result in pressure on adjacent organs. It has been suggested that 0.5 to 1 percent of the general

canine population have some form of congenital cardiac defect. Approximately 10 percent of these anomalies are vascular ring formations with the persistent right aortic arch being the most common type (2). Vascular ring anomalies (VRAs) are a common cause of regurgitation, and a persistent right aortic arch (PRAA) usually results in a dilated esophagus in young dogs (3-5). Regurgitation is described as a passive retrograde expulsion of gastric or esophageal contents. It may occur shortly after eating, or may be delayed for several hours or more. The distinction

* E-mail: yalcine@uludağ.edu.tr

from vomiting is made after the observation of undigested food, a basic pH, and lack of bilirubin in the vomited material (6). The diagnosis is mostly based on clinical examination, observation of a dilated esophagus, and constriction of the esophagus at the base of the heart after contrast esophagram. Medical treatment of PRAA has been unrewarding (1,7). The present case may be a good model for the practitioners during diagnostic work-up of regurgitation in a clinical setting, as electrocardiographic (ECG) and echocardiographic evaluations were performed in addition to clinical, laboratory, and radiological examinations.

Case History

A 12-week-old, 5 kg, intact, male German shepherd dog was presented to the Small Animal Clinic, Veterinary Faculty, University of Uludağ, Bursa, Turkey, with the history of poor weight gain and regurgitation occurring 3 to 4 times during a whole day since weaning time. The dog was much smaller than his littermates.

Results and Discussion

On physical examination, the dog was unusually thin and had a distended abdomen. Rectal temperature was 36.0 °C, while heart and respiratory rates were 80 beats per minute and 24 breaths per minute, respectively. Capillary refilling time was slightly prolonged and peripheral pulse quality was weakened. The cervical esophagus of the animal was palpable as a flaccid and air-filled cavity. Thoracic auscultation revealed normal lung, but muffled heart sounds. ECG showed small complex of QRS (0.7 mV/lead II) with a sinus arrhythmia. Echocardiographic examination was performed using standard imaging techniques (Esoate, Caris Plus, Italy). Diastole and systole diameters of left ventricle (LV) and interventricular septum (IVS) were lower, but functional parameters of the heart (ejection fraction: 69%, and fractional shortening: 36%) were within normal limits compared to reference values (8). Doppler appearances of aortic flow were normal. Flow velocity integral and maximal velocity (V_{max}) of aortic flow were 0.11 m (reference: 0.14 m) and 0.60 m/s (reference: 1.06-2.29 m/s), respectively. Peak E and A velocities of mitral valve were 0.52 m/s (reference: 0.59-1.18 m/s) and 0.36 m/s (reference: 0.33-0.93 m/s), respectively, and the E/A ratio was 1.43 (reference: >1.0).

Survey radiography of the thorax revealed a 6 cm × 9.5 cm air-filled, multi-lobulated structure, presumed to be the esophagus craniodorsal of the heart (Figure 1). Contrast material (barium sulphate) accumulation in the thoracic esophagus was consistent with a VRA (Figure 2). Routine hemogram (CellDyn-3500, Abbott Laboratories, Abbott Park, IL, USA) and serum biochemistry profile (Comprehensive Profile, VetScan, Germany) were within reference limits (9), except for slight neutrophilic leukocytosis and pre-renal azotemia. Based on these findings, surgical operation was decided for the following day. In the meantime, the dog was treated with intravenous fluids, 50 ml/kg/q12h (Lactated Ringers in 5% Dextrose, Eczacıbaşı, Turkey); intravenous antibiotics, 20 mg/kg/q12h (ampicillin with sulbactam, Ampicid flakon, Mustafa Nevzat, Turkey); a gastrointestinal prokinetic, 0.4 mg/kg/q8h, intramuscularly (metoclopramide, Metpamid 10 mg amp., Yeni, Turkey); and vitamin, 1 ml/q24h, intramuscularly, (B-complex vitamins, Bemiks ampul, Eczacıbaşı, Turkey). Despite supportive therapy, the patient deteriorated and died. At necropsy, arcus aorta, which is normally to the right of the bifurcation trachea, was transposed towards the left of the trachea and esophagus. A 35-mm PRAA, enclosing the esophagus and compressing it against the trachea, was seen between the truncus pulmonalis and aorta descendens (Figure 3). No sign of aspiration pneumonia was observed.

To date, there have been limited data on the congenital vascular anomalies observed in small animal

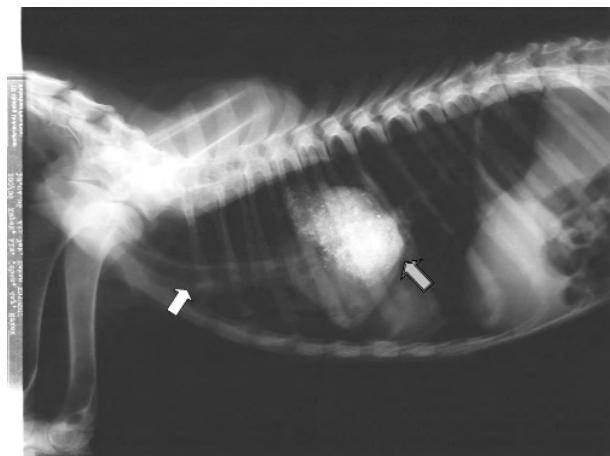

Figure 1. Survey radiograph showing the widened thoracic esophagus (white arrow) and radiocontrast food accumulation at the thoracic inlet (gray arrow).

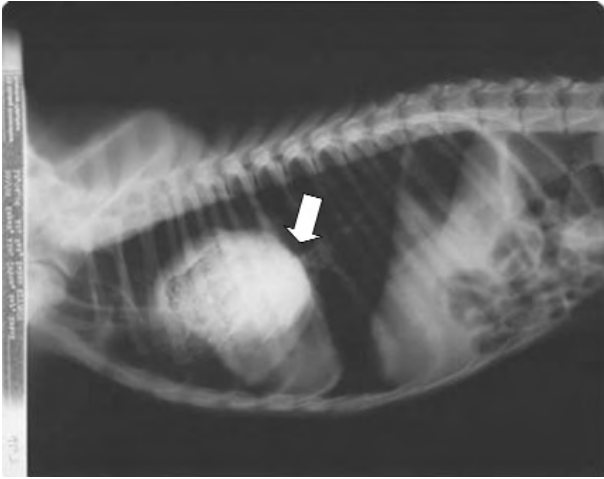


Figure 2. Lateral thoracic radiographs showing contrast material accumulation in the esophagus at the thoracic inlet and craniodorsal to the heart (white arrow) in dog with PRAA.

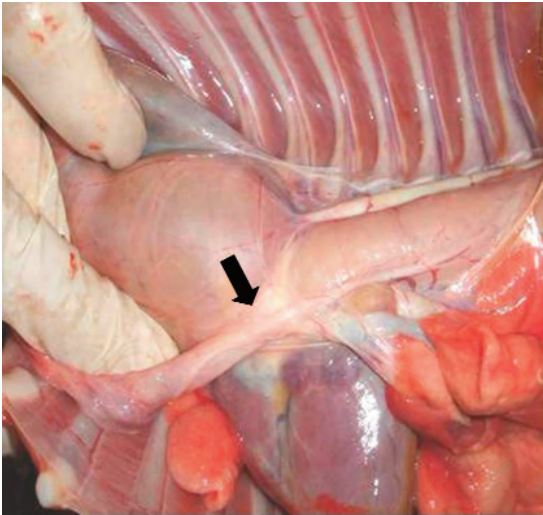


Figure 3. A 35-mm persistent right aortic arch, enclosing the esophagus and compressing it against the trachea, was seen between the truncus pulmonalis and aorta descendens (black arrow).

practice in Turkey: a German shepherd dog with PRAA (5) and a Siamese cat with double aortic arch (10). The

signalment, anamnesis, and clinical signs of the dog presented here were in accordance with other reports related with VRA (5,11,12).

Radiographic examination, rather than clinical and laboratory examinations, is crucial for the diagnosis of VRA of aorta (5,11,12). However, diagnostic importance of cardiac evaluation by ECG and echocardiographic examinations is not well-known. Low QRS voltage is generally related with the pericardial and pleural effusion, hydrothorax, and cardiomyopathy. The observation of low QRS voltage in the present dog suggests that low voltage may be important in the diagnosis of VRA. The observation of lower diastolic and systolic dimensions of LV and IVS than the reference values reported by Muzzi et al. (8) may be due to the body weight, age of the dog, and dehydration. This consideration is supported by the preserved LV functional parameters. It is interesting to note that V_{max} of aortic flow was lower (0.60 m/s) than the reported reference ranges (1.06-2.29 m/s). Observation of poor circulation signs (weak peripheral pulse quality, prolonged capillary refilling time, and pre-renal azotemia) in this case is in agreement with lower V_{max} of aortic flow and dehydration.

Definitive management of VRAs requires surgical correction of the obstruction. In cases of PRAA, ligation and transection of the ligamentum arteriosum and dissection of the fibrous bands in the esophageal wall serve to relieve the obstruction (1,4,7). The dog in the present case did not survive until the operation despite the supportive care.

In conclusion, this case report associated with VRA suggests that veterinarians should be careful about this disease in their clinical practice and include it within the differential diagnosis of postprandial regurgitation occurring with esophageal dilatation and extramural obstruction after weaning in any young dog.

References

1. VanGundy, T.: Vascular ring anomalies. *Comp. Cont. Educ. Pract. Vet.*, 1989; 11: 36-48.
2. Holmberg, D.L., Presnell, K.R.: Vascular ring anomalies: case report and brief review. *Can. Vet. J.*, 1979; 20: 78-81.
3. Buchanan, J.W.: Tracheal signs and associated vascular anomalies in dogs with persistent right aortic arch. *J. Vet. Intern. Med.*, 2004; 18: 510-514.
4. Leib, M.S.: Diseases of the esophagus. In: Leib, M.S., Monroe, W.E., Eds. *Practical Small Animal Internal Medicine*. W.B. Saunders Co., Philadelphia, 1997; 633-652.
5. Koç, Y., Turgut, K., Şen, İ., Alkan, F., Birdane, F.M.: Persistent right aortic arch and its surgical correction in a dog. *Turk. J. Vet. Anim. Sci.*, 2004; 28: 441-446.

6. Jenkins, C.C.: Dysphagia and regurgitation. In: Ettinger, S.J., Feldman, E.C., Eds. Textbook of Veterinary Internal Medicine. 5th edn., Vol. 1, W.B. Saunders Co., Philadelphia. 2000; 114-117.
7. Ellison, G.W.: Vascular ring anomalies in the dog and cat. *Comp. Cont. Educ. Pract. Vet.*, 1980; 2: 693-705.
8. Muzzi, R.A., Muzzi, L.A., De Araújo, R.B., Cherem, M.: Echocardiographic indices in normal German shepherd dogs. *J. Vet. Sci.*, 2006; 7: 193-198.
9. Bush, B.M.: Interpretation of Laboratory Results for Small Animal Clinicians. Blackwell Scientific Publications, Oxford. 1991.
10. Yarim, M., Gültiken, M.E., Öztürk, S., Sahal, M., Bumin, A.: Double aortic arch in a Siamese cat. *Vet. Pathol.*, 1999; 36: 340-341.
11. House, A.K., Summerfield, N.J., German, A.J., Noble, P.J.M., Ibarrola, P., Brockman, D.J.: Unusual vascular ring anomaly associated with a persistent right aortic arch in two dogs. *J. Small Anim. Pract.*, 2005; 46: 585-590.
12. Kim, N.S., Alam, M.R., Choi, I.H.: Persistent right aortic arch and aberrant left subclavian artery in a dog: a case report. *Vet. Med.*, 2006; 51: 156-160.