

A Comparative Study of Variation of the Pterion of Human Skulls from 13th and 20th Century Anatolia

Un Estudio Comparativo de la Variación del Pterion en Cráneos Humanos de los Siglos 13 y 20 de Anatolia

*Ari Ilknur; **Kafa Ilker Mustafa & **Bakirci Sinan

ILKNUR, A.; MUSTAFA, K. I. & SINAN, B. A comparative study of variation of the pterion of human skulls from 13th and 20th century Anatolia. *Int. J. Morphol.*, 27(4):1291-1298, 2009.

SUMMARY: The pterion is a commonly used anthropologic and neurosurgical landmark defined as the junction of the sphenoid, temporal, parietal and frontal bones. It is commonly classified into four types based on sutural pattern: sphenoparietal, in which the sphenoid and parietal bones are in direct contact; frontotemporal, in which the frontal and temporal bones are in direct contact; stellate, in which all four bones come into contact at a point; and epipterice, in which a small sutural bone is found between the parietal bone and the greater wing of the sphenoid bone. In the present study, 44 Anatolian skulls from two different eras, Byzantine (13th century) and contemporary (20th century), were investigated for morphology and location of the pterion. Sphenoparietal was the most common form, comprising 87.5% and 89.2% in the Byzantine and contemporary groups, respectively. The frequencies of the epipterice type of pterion were 6.25% and 3.6% in the Byzantine and contemporary groups, respectively. Measurements of the location of the pterion were made by using stainless steel calipers and Scion Image software. There were no significant differences in digital and manual measurements between the right and left sides of the skulls in both groups. However, the distance from the pterion to the inion was significantly greater in the manual measurements compared to the digital measurements. Anatomical variations of the pterion, which are of interest to anthropologists, forensic pathologists and surgeons, deserve further investigation in other populations from different geographical areas.

KEYWORDS: Anatolian; Anthropology; Calvarial sutures; Epipterice bone; Morphometry.

INTRODUCTION

The temporal fossa is a significant area of the skull where elements of the facial skeleton, the skull base and the calvaria converge (Urzi *et al.*, 2003; Williams *et al.*, 1998). The zygomatic arch, the temporal line, the frontozygomatic processes and the supramastoid crest delineate the temporal fossa, and the temporal muscle is attached to its floor. Temporal fossae are characterized by the presence of four distinct bony elements: the frontal and parietal bones, the greater wing of the sphenoid bone, and the squamous part of the temporal bone. All of these bones are in close proximity in a region described by a small circular area termed the pterion, located approximately 4.0 cm above the zygomatic arch and 3.5 cm behind the frontozygomatic suture (Williams *et al.*). It occurs usually as an irregularly H-shaped meeting of sutures, forming a horizontal limb between the antero-infe-

rior parietal angle and the apical border of the greater sphenoid wing (Moore, 1992).

The pterion is also an important landmark for the anterior branch of the middle meningeal artery, Broca's area (44-45), the insula, and the stem of the lateral sulcus. It is also a primary site during surgery to gain access to the sphenoid ridge and optic canal (Saxena *et al.*, 2003). The pterion is also commonly used in cranial suture closure methodology as an important guide for age estimation and sex determination in archeological and forensic specimens (Lovejoy *et al.*, 1985). Sutural patterns or bony articulations within the region of the pterion have been generalized into different types by various anthropological and clinical studies (Wang *et al.*, 2006). The pterion was first classified into three

* Prof. Dr. Department of Anatomy, Faculty of Medicine, Uludag University, Gorukle, Bursa, Turkey.

** MD. Department of Anatomy, Faculty of Medicine, Uludag University, Gorukle, Bursa, Turkey.

The work was supported by Research Foundation of Uludag University (Grant Number: T- 2003/ 32).

types (sphenoparietal, frontotemporal and stellate) by Broca in 1875. Subsequently, four types (sphenoparietal, frontotemporal, stellate, and epiptereric) were defined by Murphy (1956). More recently, Wang *et al.* proposed six types of pterions. The sphenoparietal type is defined as a sutural pattern in which the sphenoid and parietal bones are in direct contact, preventing the frontal and temporal bones making contact with one another. Conversely, the frontotemporal type is a sutural pattern in which the frontal and temporal bones are in direct contact, preventing the sphenoid and parietal bones making contact with one another. The stellate type is characterized by articulation of four bones (frontal, parietal, temporal and sphenoid) at a point. The epiptereric type is defined by presence of a small sutural bone between the parietal bone and the greater wing of the sphenoid bone. The zygomaticoparietal type is a sutural pattern in which the zygomatic bone has a tongue extending to the parietal bone, thus separating the frontal bone from either the sphenoid or temporal bone (a variation of the sphenoparietal type). The zygomaticotemporal type is defined as a sutural pattern in which the zygomatic bone is elongated to meet the temporal bone, separating the sphenoid bone from the frontal and parietal bones (considered a subtype of the frontotemporal type) (Murphy; Saxena *et al.*; Wang *et al.*).

In the present study, pterional types from a 13th century Anatolian archeological population were examined and compared with pterional types obtained from a contemporary Anatolian population. Distances to neighboring structures of the pterion were also measured and data from the two populations were compared.

MATERIAL AND METHOD

A total of 44 dry skulls of Byzantine and Turkish adults aged 30 to 50 years were studied. Twenty-eight skulls (unknown sex) were from a contemporary Turkish population (20th century) from the Marmara region of Turkey, and 16 skulls (male) excavated in 1984 from an archeological site in Nicea (Iznik, Turkey) were assigned to the Late Byzantine period (13th century) (Ozbek, 1984). All samples were stored and preserved in the Department of Anatomy, Faculty of Medicine, Uludag University, Bursa, Turkey.

On both the left and right sides of each skull, the sutural pattern of the pterion was determined based on descriptions (sphenoparietal, frontotemporal, stellate and epiptereric types) by Murphy (1956) and Saxena *et al.*, following Oguz *et al.* (2004) (Fig. 1).

Manual and digital approaches were used together to measure the cranium. For the epiptereric type, a circle of smallest radius connecting the corners of the sutural bone was drawn and the center of this circle was taken as the center of the pterion. Measurements of distances between the pterion and specific identifiable bony landmarks were made using calibration, line tracing, and the measuring features of Scion Image software. Digital photos were obtained with a Sony DSC-F717 digital camera prior to the taking measurements digitally. Manual measurements were made by using a caliper prior to taking the digital measurements. Definitions of the measurements were derived from previous studies of others (Fig. 2) (Saxena *et al.*; Matsumura *et al.*, 1991; Asala & Mbajjorgu, 1996; Urzi *et al.*; Oguz *et al.*). Parameters used in the present study are as follows:

PSFZ: distance from the center of the pterion to the anterior aspect of the sutura frontozygomatica,

PSTZ: distance from the center of the pterion to the superior aspect of the sutura temporozygomatica,

PAZ: the vertical distance from the center of the pterion to the arcus zygomaticus, perpendicular to a reference line which is between the most inferior part of the processus mastoideus and most inferior-posterior part of the maxilla,

PFM: distance from the center of the pterion to the base of the fossa mandibularis,

PSS: distance from the center of the pterion to the center of the spina supraceutica,

PA: distance from the center of the pterion to the center of the asterion,

PPM: distance from the center of the pterion to the most inferior aspect of the processus mastoideus,

PI: distance from the center of the pterion to the most posterior aspect of the inion.

The SPSS 16 statistical program for Windows was used for analysis of all measurements (Mann-Whitney U test) and for evaluation between the manual and digital methods (Wilcoxon test). Means and standard deviations were also calculated for each measurement.

RESULTS

Three types of pterions (sphenoparietal, frontotemporal and epiptereric) were found in both the Byzantine (n=16) and contemporary populations (n=28) (Table I). The sphenoparietal pterion was the predominant type in both groups [14/16 (87.5%) in the Byzantine group and 25/28 (89.2%) in the contemporary group]. Single examples of frontotemporal and epiptereric types were also

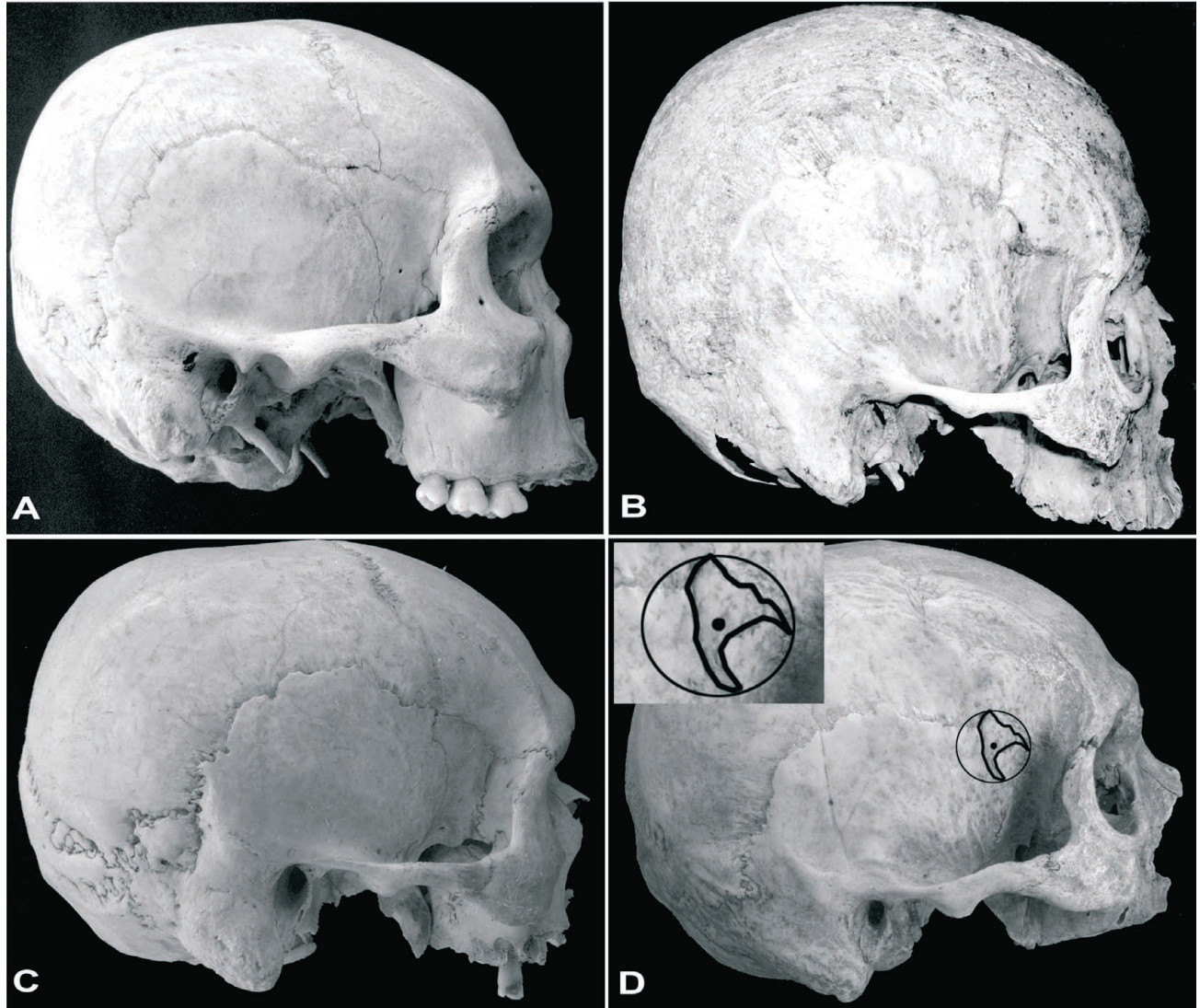


Fig. 1. Types of pterions; A: Sphenoparietal, B: Frontotemporal, C: Stellate, D: Epipterical (a circle with the smallest radius connecting the corners of the sutural bone was drawn, and the center of this circle was taken as the center of the pterion).

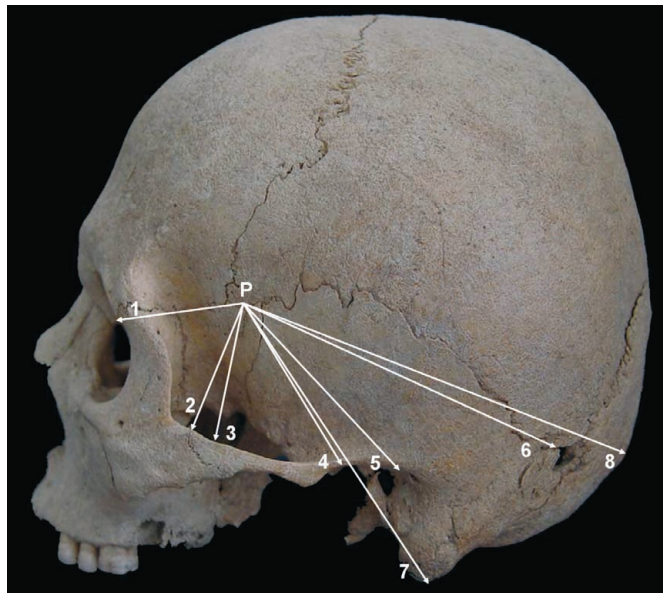


Fig. 2. Linear measurements related to the pterion and neighboring structures of the Byzantine and contemporary groups.

observed in both groups. A single stellate type was observed in contemporary group but none was observed in the Byzantine group (Table I). There were no cases of asymmetry in either group.

The means of the linear measurements are presented in Table II. No significant differences between the Byzantine and contemporary groups were observed for linear measurements ($p>0.05$). However, the “PI” parameter was significantly higher in the manual measurements compared

to the digital measurements ($p<0.05$). This difference presumably reflects the two-dimensional approach of the digital measurements. Because of the midsagittal location of the inion, it is located more distant from the pterion when the measurement is taken manually. By ignoring the “PI” parameter, other parameters could be obtained from digital measurements without important differences from the manual measurements. In addition, there were no significant differences in linear measurements of the pterion between the right and left sides of the skulls in both groups.

Table I. Distribution of pterional types among skulls of Byzantine and contemporary groups.

Pterional type	Byzantine group (n=16)		Contemporary group (n= 28)	
	%	n	%	n
Sphenoparietal	87.5	14	89.2	25
Frontotemporal	6.25	1	3.6	1
Stellate	0.0	-	3.6	1
Epipteric	6.25	1	3.6	1

Table II. Means and standard deviations of linear distances (cm) from the pterion to specific identifiable bony landmarks on Byzantine (13th century) and contemporary Anatolian skulls.

	Byzantine group N = 28		Contemporary group N =16	
	Mean±SD cm	Digital/Manual	Mean±SD cm	Digital/Manual
	Right side	Left side	Right side	Left side
PSFZ	3.5±0.4/3.9±0.4	3.7±0.5/3.9±0.42	3.5±0.5/3.8±0.5	3.5±0.5/4.1±0.7
PSTZ	3.5±0.3/4.1±0.45	3.8±0.1/4.2±0.49	3.9±0.4/4.3±0.3	3.9±0.5/4.7±0.3
PAZ	3.7±0.2/4.5±0.4	3.8±0.1/3.9±0.46	3.8±0.4/4.2±0.3	3.9±0.4/4.3±0.2
PFM	4.7±0.4/4.7±0.4	4.7±0.5/4.8±0.29	4.7±0.3/4.7±0.5	4.8±0.3/4.8±0.4
PSS	5.7±0.3/5.7±0.4	5.7±0.4/5.9±0.35	5.8±0.4/5.8±0.4	5.1±0.4/5.9±0.3
PA	8.4±0.6/8.9±0.4	8.5±0.6/9.3±0.65	8.4±0.7/8.7±0.7	8.5±0.8/8.6±0.8
PPM	7.8±0.4/8.3±0.34	7.9±0.5/8.5±0.26	7.7±0.5/8.2±0.5	7.8±0.5/8.1±0.7
PI	10.2±0.8/13.8±0.5	10.7±0.5/13.7±0.4	10.4±0.6/13.6±0.8	10.5±0.6/13.6±0.6

DISCUSSION

It is well known that the morphological configuration of the sutural junctions of the bones associated with the pterion varies significantly in humans. Previous studies of the configuration of sutural articulation patterns associated with the pterion have focused principally on variation, classification, presence of epipteric bones, and associated cranial measurements and indexes (Urzi *et al.*; Wang *et al.*). Population-based differences suggest that various genetic variations in humans underlie the different sutural patterns of the pterion (Wang *et al.*). Murphy reported that variations of the pterion are likely a result of a combination of

environmental and genetic factors. Asala & Mbajjorgu concluded that these variations are “epigenetic”. Wang *et al.* examined variations in sutural patterns at the pterion in rhesus monkey pedigrees and stated that the variants show familial aggregation, likely regulated by genes. However, contributions of developmental or environmental factors to the observed variations at the pterion region remain to be investigated.

Development of the calvarial bones is tightly coordinated with the growth of the brain and requires

interactions between different tissues within the calvarial sutures (Kim *et al.*, 1998; Wang *et al.*). Ashley-Montagu (1930) reported that the pterion is subject to innumerable variations and the essential factor in determining these modifications should be sought in the process of cranial expansion during development. Genetic knowledge of how contemporary variation in sutural patterns at the pterion came to exist in both humans and nonhuman primates will also provide insights into how morphological variations and evolutionary changes are patterned in the craniofacial region (Wang *et al.*). Understanding how sutural configuration, brain growth, and developmental patterns are linked will require further study. Investigation of sutural configurations at the pterion in primate and human fossils, as well as sutural patterns following experimentally modified growth through transgenic techniques, will help to elucidate the causes of variation and the evolution of sutural and skull morphology (Wang *et al.*).

According to previous studies, the sphenoparietal type of pterion is the dominant form in humans whereas the frontotemporal type is dominant in nonhuman primates (Ashley-Montagu, 1933; Saxena *et al.*, 1988; Aiello & Dean 1990; Matsumara *et al.*; Asala & Mbajjorgu; Lee *et al.*, 2001; Saxena *et al.*, 2003; Oguz *et al.*). In primate evolution, the anterosuperior segment of the squamosus part of the temporal bone of lower primates became detached from its parent and incorporated into the posterosuperior angle of the greater wing of the sphenoid bone of humans, thereby changing the pterion pattern from the frontotemporal type of nonhuman primates to the sphenoparietal type of humans (Ashley-Montagu, 1930; Saxena *et al.*, 2003). Our results are in agreement with the previous studies of pterion types in humans (Table III).

The different types and locational differences of the pterion and its relationship to surrounding bony landmarks

have been defined in different populations, and this knowledge is important in neurosurgery. The pterional approach, which is used in neurosurgery, has been described as the most popular approach (Yasargil *et al.*, 1975; Yasargil *et al.*, 1987). It represents the standard approach for most lesions of the anterior and middle cranial fossae. The pterional approach is commonly employed in surgical treatment of the anterior circulation and upper basilar artery aneurysms, as well as for the tumors of orbital, retroorbital, sellar, chiasmatic, subfrontal and prepontine areas, lesions around the sella, and especially for lesions behind the clivus (Samson *et al.*, 1978; Aydin *et al.*, 1995; Nanda *et al.*, 2001; Andaluz *et al.*, 2003; Tomasello *et al.*, 2003; Ananthanandorn & Prachasinchai, 2004; Cardali *et al.*, 2005; Ammirati & Bernardo, 2007). The pterion has been reported to lie 4.0 cm above the arcus zygomaticus and 3.5 cm behind the sutura frontozygomatica (Moore; Williams *et al.*). In the present study, we observed distances similar to the above values in both populations investigated. These results collectively suggest that the location of the pterion were not significantly different between the Anatolian populations of two different eras. Similar findings by Oguz *et al.* in other Anatolian skulls would further lend support to this assumption. In contrast, Saxena *et al.* (1988) reported a more superiorly situated pterion (its distance from the arcus zygomaticus is greater) in Nigerians on both sides and a more caudally situated pterion (its distance from the sutura frontozygomatica is greater) in Indians on the right side.

The percentages of epipteric pterions were found to be 6.25% (Byzantine) and 3.6% (contemporary) in our study, and these findings are similar to those reported for other Anatolian skulls (Oguz *et al.*). However, Lee *et al.*; Manjunath & Thomas (1993) and Braga *et al.* (2000) all reported higher percentages of epipteric pterions among Korean (40.3%), Indian (17.3%) and Brazilian (15.1%) populations, respectively (Table IV). These different results

Table III. Comparison of the percentages of pterional types in different populations

Study/Population n (skull), sex	Type of the pterion		
	Sphenoparietal %	Frontotemporal %	Stellate %
Saxena <i>et al.</i> , 1988, Nigerian, n= 40, unknown sex	84.79	10.11	5.06
Saxena <i>et al.</i> , 1988, Indian, n= 72, unknown sex	95.3	3.46	1.38
Manjunath <i>et al.</i> , 1993, Indian, n= 172, unknown sex	93.55	3.52	2.93
Asala <i>et al.</i> , 1996, Nigerian, n= 212, unknown sex	82.1	23.6	-
Lee <i>et al.</i> , 2001, Korean, n= 149, unknown sex	76.5	-	-
Saxena <i>et al.</i> , 2003, Indian, n= 203, both sex	84.72	10.01	5.17
Oguz <i>et al.</i> , 2004, Turkish, n= 26, male	88	10	0
Present study, Byzantine period, n= 16, male	87.5	6.25	0
Present study, Contemporary period, n= 28, unknown sex	89.2	3.6	3.6

presumably are related to the racial characteristics of the different populations.

The distinctive characteristics of the pterion observed in different populations, racial groups and species result from differences in skull formation. Distances between the pterion and neighboring structures have importance in surgical approaches related to the cranium. It has been noted that accurate knowledge of the location of the pterion and the relationship of the pterion to significant anatomical structures are important for surgical intervention, particularly with respect to the course of the branches of the middle meningeal

artery and Broca's motor speech area on the left side (Oguz *et al.*). Therefore, the anatomical varieties of the pterion, which have been of interest mainly to anthropologists and forensic pathologists, deserve further investigation in other geographical areas and different populations. Such findings could also be useful for assessing the location of the pterion in incomplete archeological remains or forensic materials.

ACKNOWLEDGEMENTS. The work was supported by Research Foundation of Uludag University (Grant Number: T- 2003/ 32).

Table IV. Comparison of epipteric pterion frequencies in different populations

Population	Nigerian	Indian	Japanese	Indian	Nigerian	Brazilian	Korean	Turkish	Turkish	Byzantine period	Contemporary period
Study	Saxena <i>et al.</i> , 1988	Saxena <i>et al.</i> , 1988	Matsumara <i>et al.</i> , 1991	Manjunath <i>et al.</i> , 1993	Asala <i>et al.</i> , 1996	Braga <i>et al.</i> , 2000	Lee <i>et al.</i> , 2001	Ersoy <i>et al.</i> , 2003	Oguz <i>et al.</i> , 2004	Present study	Present study
Epipteric type of pterion %	3.79	11.79	10	17.3	5.7	15.1	40.3	9	2	6.25	3.6
N skull	40	72	356	172	212	205	149	300	26	16	28

ILKNUR, A.; MUSTAFA, K. I. & SINAN, B. Un estudio comparativo de la variación del pterion en cráneos humanos de los siglos 13th y 20th de Anatolia. *Int. J. Morphol.*, 27(4):1291-1298, 2009.

RESUMEN: El pterion es un punto comúnmente usado como punto de referencia antropológico y neuroquirúrgico, correspondiendo a la unión de los huesos esfenoides, temporal, parietal y frontal. Generalmente es clasificado en 4 tipos basado en padrones suturales: esfenoparietal, en el cual los huesos esfenoides y parietal están directamente en contacto; frontotemporal, en el cual el frontal y el temporal se encuentran en contacto directo; estrellado, en el cual los cuatro huesos mencionados se contactan directamente en un punto y epiptérico, en el cual un pequeño hueso sutural se encuentra entre el hueso parietal y el ala mayor del esfenoides. En el presente estudio, investigamos la morfología y la localización del pterion en 44 cráneos Anatolian de diferentes épocas, Bizantina (Siglo XIII) y contemporánea (Siglo XX). La forma más común que se encontró fue la Esfenoparietal, con un 87,5 % para los del grupo Bizantino y 89,2 % para los de la era contemporánea. La frecuencia del tipo epiptérico fue de 6,25 % y 3,6 %, respectivamente. Se realizaron medidas de la posición del pterion utilizando un caliper y un software de imágenes. No hubo diferencias estadísticamente significativas en las mediciones manuales y digitales entre los lados derecho e izquierdo de los cráneos de ambos grupos. Sin embargo, la distancia desde el pterion al ionion fue significativamente mayor en las medidas manuales comparadas con las digitales. Las variaciones anatómicas del pterion, las cuales son de interés para antropólogos, patólogos forenses y cirujanos, son un tema de investigación a desarrollar en otras poblaciones de diferentes áreas geográficas.

PALABRAS CLAVE: Anatolia; Antropología; Suturas craneales; Hueso epiptérico; Morfometría.

REFERENCES

- Aiello L, Dean C. *An introduction to human evolutionary anatomy*. London, Academic Press, 1990.
- Ammirati, M. & Bernardo, A. Anatomical study of the superior orbital fissure as seen during a pterional approach. *J. Neurosurg.*, 106:151-6, 2007.
- Ananthanandorn, A. & Prachasinchai, P. The comparison of conventional pterional and transclivary keyhole approaches: *Proc. and Con. J. Med. Assoc. Thai.*, 87(8):891-7, 2004.
- Andaluz, N.; Van Loveren, H.R.; Keller, J.T. & Zuccarello, M.. The one-piece orbitopterional approach. *Skull Base*, 13(4):241-6, 2003.

- Asala, S.A. & Mbajiorgu, F.E. Epigenetic variation in the Nigerian skull: sutural pattern at the pterion. *East. Afr. Med. J.*, 73(7):484-6, 1996.
- Ashley-Montagu, F.M. The tarsian hypothesis and the descent of man. *J. R. Anthropol. Inst. Great Britain Ireland*, 60:335-62, 1930.
- Ashley-Montagu, F.M. The anthropological significance of the pterion in the Primates. *Am. J. Phys. Anthropol.*, 18:159-336, 1933.
- Aydin, I.H.; Takci, E.; Kadioglu, H.H.; Kayaoglu, C.R. & Tuzun, Y. Pitfalls in the pterional approach to the parasellar area. *Minim. Invasive. Neurosurg.*, 38:146-52, 1995.
- Braga, M.T.T.; Gabrielli, C. & De Souza, A. Sutural bones in the pterion. *Rev. Chil. Anat.*, 18(1):97-101, 2000.
- Cardali, S.; Romano, A.; Angileri, F.F.; Conti, A.; La Torre, D.; de Divitiis, O.; d'Avella, D.; Tschabitscher, M. & Tomasello, F. Microsurgical anatomic features of the olfactory nerve: relevance to olfaction preservation in the pterional approach. *J. Neurosurg.*, 57:17-21, 2005.
- Ersoy, M.; Evliyaoglu, C.; Bozkurt, M.C.; Konuksan, B.; Tekdemir, I. & Keskil, I.S. Epipteric bones in the pterion may be a surgical pitfall. *Minim. Invasive. Neurosurg.*, 46:363-5, 2003.
- Kim, H.J.; Rice, D.P.C.; Kettunen, P.J. & Thesleff, I. FGF-, BMP- and Shh-mediated signaling pathways in the regulation of cranial suture morphogenesis and calvarial bone development. *Development*, 125:1241-51, 1998.
- Lee, U.Y.; Park, D.K.; Kwon, S.O.; Paik, D.J. & Han, S.H. Morphological analysis of the pterion in Korean. *Korean J. Phys. Anthropol.*, 14(4):281-9, 2001.
- Lovejoy, C.O.; Meindl, R.S.; Mensforth, R.P. & Barton, T.J. Multifactorial determination of skeletal age at death: a method a blind tests of its accuracy. *Am. J. Phys. Anthropol.* 68(1):1-14, 1985.
- Manjunath, K.Y. & Thomas, I.M. Pterion variants and epipteric ossicles in South Indian skulls. *J. Anat. Soc. India*, 42(2):85-94, 1993.
- Matsumara, G.; Kida, K.; Ichikawa, R. & Kodama, G. Pterion and epipteric bones in Japanese adults and fetuses, with special reference to their formation and variations. *Acta Anatomica Nipponica (Kaibogaku Zasshi)*, 66(5):462-71, 1991.
- Moore, K.L. Clinically orientated anatomy. 3th edn., Williams & Wilkins, pp. 641-642, Baltimore, 1992.
- Murphy, T. The pterion in the Australian aborigine. *Am. J. Phys. Anthropol.*, 14:225-44, 1956.
- Nanda, A.; Vannemreddy, P.S. & Vincent, D.A. Microsurgical and endoscopic approaches to the basilar bifurcation: quantitative comparison of combined pterional/anterior temporal and orbitozygomatic extended approaches. *Skull Base*, 11(2):93-7, 2001.
- Oguz, O.; Sanli, S.G. & Bozkir, M.G. & Soames, R.W. The pterion in Turkish male skulls. *Surg. Radiol. Anat.*, 26:220-4, 2004.
- Ozbek, M. Roma açık hava tiyatrosundan (Izmit) çıkartılan Bizans iskeletleri. *Hacettepe Universitesi Edebiyat Fakultesi Dergisi*, 2:81-9, 1984.
- Samson, D.S.; Hodosh, R.M. & Clark, W.K. Microsurgical evaluation of the pterional approach to aneurysms of the distal basilar circulation. *Neurosurgery*, 3(2):135-41, 1978.
- Saxena, S.K.; Jain, S.P. & Chowdhary, D.S. A comparative study of pterion formation and its variations in the skulls of Nigerians and Indians. *Anthropol. Anz.*, 46(1):75-82, 1988.
- Saxena, R.C.; Bilodi, A.K.S.; Mane, S.S. & Kumar, A. Study of pterion in skulls of awadh area-in around Lucknow. *Kathmandu Univ. Med. J.*, 1(1):32-3, 2003.
- Tomasello, F.; de Divitiis, O.; Angileri, F.F.; Salpietro, F.M. & d'Avella, D. Large sphenocavernous meningiomas: is there still a role for the intradural approach via the pterional-transsylvian route? *Acta Neurochir.*, 145(4):273-82, 2003.
- Urzi, F.; Iannello, A.; Torrisi, A.; Foti, P.; Mortellaro, N.F. & Cavallaro, M. Morphological variability of pterion in the human skull. *Ital. J. Anat. Embryol.*, 108:83-117, 2003.
- Wang, Q. ; Opperman, L.A. ; Havil, L.M. ; Carlson, D.S. & Dechow, P.C. Inheritance of sutural pattern at the pterion in Rhesus Monkey skulls. *Anat. Rec. Discov. Mol. Cell. Evol. Biol.*, 288:1042-9, 2006.
- Williams, L. P.; Bannister, L. H.; Berry, M. M.; Collins, P.; Dyson, M.; Dussek, J.E.; & Ferguson, M.W. J. *Gray's Anatomy*. 38th edn., Churchill Livingstone, pp. 568, 595, 1912, 1519, London, 1988.

Yasargil, M.G.; Fox, J.L. & Ray, M.W. The operative approach to aneurysms of the anterior communicating artery. *Advances and Technical Standards in Neurosurgery*, 2:113-70, 1975.

Yasargil, M.G.; Reichman, M.V. & Kubin, S. Preservation of the frontotemporal branch of the facial nerve using the interfacial temporalis flap for pterional craniotomy: Technical article. *J. Neurosurg.*, 67:463-6, 1987.

Correspondence to:
Prof. Dr. Ilknur Ari
Uludag University
Faculty of Medicine
Department of Anatomy
16059, Gorukle, Bursa
TURKE

Phone number: +90 224 442 88 08
Fax number: +90 224 441 75 35

Email: iari@uludag.edu.tr

Received: 21-06-2009

Accepted: 13-07-2009