

# Abdominal Wall Ruptured by Blunt Trauma in a Child

Nizamettin Kılıç, Emin Balkan, İrfan Kırıştıoğlu, Neşe Güney and Hasan Doğruyol

From the Department of Paediatric Surgery, The Medical Faculty of Uludağ University, Görükle, Bursa, Turkey

Eur J Surg 2000; 166: 265–266

## INTRODUCTION

Traumatic abdominal wall hernias are uncommon in children (3), and the first reported case that we could find was presented by Selby in 1906 (10). These injuries are often devastating, and accompanied by other serious injuries and complications (8). In this case report we present a child in whom blunt abdominal trauma caused such a hernia and describe our findings and treatment.

## CASE REPORT

A 4-year-old boy was admitted to the emergency department with a crush injury caused by his being pinned between a car and a wall. On admission he was unconscious and shocked. He was quickly intubated and ventilated mechanically. On physical examination he had bilateral subconjunctival haemorrhages, cervicofacial cyanosis, a  $7 \times 7 \times 5$  cm right-sided fluctuant swelling over the thoracic cage, bruising and ecchymosis of the periumbilical region, and a fracture of the left humerus. His breath sounds were normal on both sides, and his upper abdomen was tender with moderate guarding.

An anteroposterior chest radiograph was clear with no evidence of pneumothorax or haemothorax, but a lateral view showed bowel loops within the presternal soft tissue at the lower edge of the thorax (Fig. 1). A thoracic computed tomogram (CT) showed intestinal loops protruding into the presternal and right lower thoracic regions, but the diaphragm was intact (Fig. 2). The CT also showed grade I liver and grade IV splenic injuries, but the left kidney was not visible.

On the clinical and radiological findings we diagnosed intra-abdominal solid organ injuries and rupture of the abdominal wall and the patient was taken to the operating theatre four hours after admission. Fluid and blood replacement was given intravenously because of persistent hypotension. Through a vertical midline incision we found a fascial defect 4 cm in length in the linea alba and the right rectus abdominis, through which small intestine had passed into the subcutaneous tissues of the anterior and right side of the chest wall.

There was massive intra-abdominal haemorrhage, a bleeding paranchymal laceration 1 cm in depth in the liver and a shattered spleen with hilar disruption (grade IV). The left renal pedicle was injured and the kidney was shattered together with damage to the distal pancreas. The liver was sutured and the spleen, left kidney, and distal pancreas were removed. Herniated ileal loops looked normal and were easily reduced into the abdomen. The defect was repaired primarily with interrupted non-absorbable sutures and a sump drain was placed in the presternal subcutaneous region. His postoperative recovery was uneventful and he was discharged on the eighth postoperative day.

## DISCUSSION

Abdominal wall hernias caused by blunt trauma in children are rare (8), and motor vehicle crashes and pedestrian injuries are the most common mechanisms of injury (3). The pathophysiology involves the sudden application of a blunt force to the abdomen over an area large enough to prevent penetration of the skin. Forces applied tangentially to the abdominal wall can transmit a formidable shear stress to the muscles, fascia, and peritoneum, and disrupt the abdominal wall. The skin is the most elastic of these structures so remains intact, resulting in subcutaneous herniation of the abdominal viscera through the resulting defect (6) as in our case.

Clain described three types of traumatic abdominal hernia: type I is caused by injury to the conjoint tendon; type II comprises a tear in the rectus abdominis muscle remote from the inguinal region; and type III is when the rectus abdominis muscle is separated from the pubic bone (2). Our patient had a type II hernia. These have been reported after traffic accidents, falling from a high level, and after goring by animals (1, 2, 4, 9, 11).

The physical findings in these patients are: subcutaneous fluctuant swelling, bruising, and ecchymosis of the abdominal wall. The fascial edges of the hernial defect may not be palpable because of the oedema and tenderness (3). These findings were present in this case, as well as the thoracic asphyxia syndrome.

CT gives the most definitive diagnostic accuracy, but

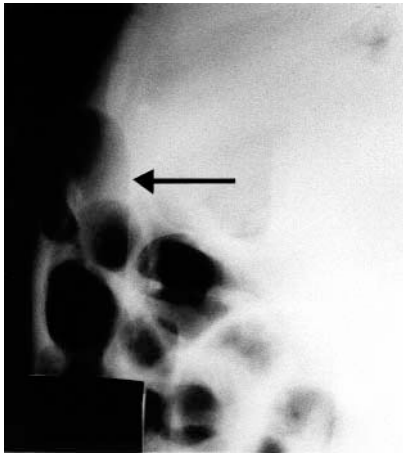


Fig. 1. Lateral chest radiograph showed bowel loops within the presternal soft tissue at lower edge of the thorax.

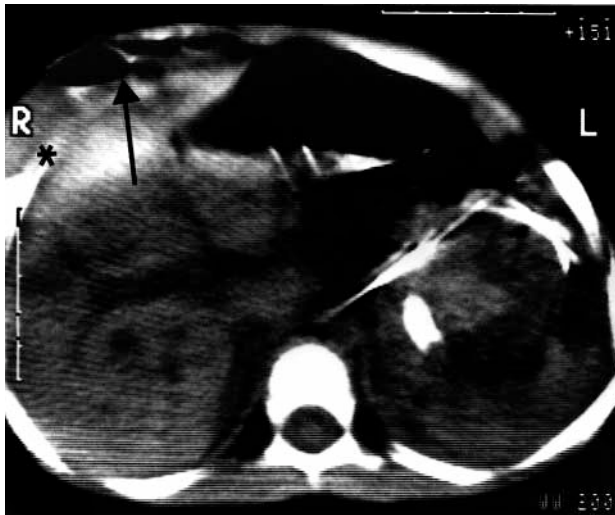


Fig. 2. A thoracic CT showing protrusion of intestinal loops to the presternal and right lower thoracic region with intact diaphragm.

conventional radiographs should not be underestimated (5, 7, 12). The differential diagnosis includes haematoma of the rectus sheath and pre-existing abdominal wall tumour or hernia (3). In our patient the definite diagnosis was made by using a lateral radiograph and thoracoabdominal CT.

If there is an obvious abdominal wall injury or defect, associated injuries must be suspected (8). Our patient had a fractured left humerus, and massive intra-abdominal haemorrhage from hepatic, splenic, renal, and distal pancreatic injuries.

Careful consideration should be given to the repair, the principles of which include adequate debridement of devitalised and contaminated tissue; direct primary repair of the defect when possible; and the use of fascial grafts and prosthetic materials when needed. In

our patient the fascial defect was repaired primarily without an autologous graft or prosthetic material. In a severely injured patient, reconstruction of the abdominal wall should be delayed until the patient's life is no longer at risk (8). Many complications such as haematoma, infection, wound dehiscence, thromboembolism, atelectasis, recurrent hernia, bowel obstruction, and fistulas can be encountered in the postoperative period (13).

When treating a child with such a hernia, particular attention must be paid to the associated injuries and surgical management.

## REFERENCES

1. Atiems EA, Goswami G. Traumatic ventral hernia. *J Trauma* 1974; 14: 181–183.
2. Clain A. Traumatic abdominal hernia. *Injury* 1974; 5: 298–300.
3. Çiftçi AO, Salman B, Türken A, Senocak ME. Acute blunt traumatic abdominal hernia. *J Pediatr Surg* 1997; 32: 1732–1734.
4. Dajie H, Nicholson DM. Traumatic abdominal hernia. *J Trauma* 1979; 19: 710–713.
5. Fredlund P, Dahn I. Traumatic subcutaneous rupture of the abdominal wall with intestinal prolapse. *Acta Chir Scand* 1967; 133: 501–503.
6. Ganchi PA, Dennis PO. Autopenetrating hernia: a novel form of traumatic abdominal wall hernia—case report and review of the literature. *J Trauma* 1996; 41: 1064–1066.
7. Kaude J. Traumatic rupture of the abdominal wall with subcutaneous herniation of the transverse colon and perforation of the small bowel. *Br J Radiol* 1966; 39: 950–951.
8. Metzdorf MT, Miller SH, Smiley P, Klabacha ME. Blunt traumatic rupture of the abdominal wall musculature. *Ann Plast Surg* 1984; 13: 63–66.
9. Payne DD, Resnikoff SA, States JD, Williams JS. Seat belt abdominal wall muscular avulsion. *J Trauma* 1973; 13: 262–265.
10. Selby CD. Direct abdominal hernia of traumatic origin. *JAMA* 1906; 47: 1485–1487.
11. Venkararaman MD. Traumatic herniation through the abdominal wall. *J Indian Med Assoc* 1967; 48: 122–124.
12. Wechsler RJ, Kurtz AB, Needleman L. Cross sectional imaging of abdominal wall hernias. *AJR* 1989; 153: 517–520.
13. Wilson W, Winegarner F, Muir RS. Management of massive abdominal wall defects. *Am Surg* 1975; 41: 249–252.

Submitted July 25, 1998; submitted after revision September 22, 1998; accepted November 30, 1998

### Address for correspondence:

Hasan Doğruyol, M.D.  
Uludağ Üniversitesi Tıp Fakültesi  
Çocuk Cerrahisi Anabilim Dalı  
Görükle  
TR-16059 Bursa  
Turkey