

Histological Investigations on the Effects of Feeding with a Diet Containing Red Hot Pepper on the Reproductive System Organs of the Cock

Aytekin ÖZER*, Berrin ZİK, Hatice ERDOST, Nesrin ÖZFİLİZ

Department of Histology and Embryology, Faculty of Veterinary Medicine, Uludağ University, 16059, Bursa - TURKEY

*E-mail: aytek@uludag.edu.tr

Received: 13.11.2002

Abstract: In the present study the growth and reproductive organ structural differences in cocks fed a diet containing 1% red hot pepper (10 g/kg diet) from the first day of age were investigated. In cocks fed the experimental diet body weight gain decreased; testes weight, length, width and wall thickness of the tubuli seminiferi convoluti increased; and the completion of spermatogenic cell serial formation took place earlier compared to the control group.

Key Words: Red hot pepper, cock, reproductive organs

Horozlarda Acı Kırmızı Biberli Rasyonla Beslemenin Reprodüktif Sistem Organları Üzerine Etkisinin Histolojik Yönden İncelenmesi

Özet: Sunulan bu çalışmada, yemlerine % 1 (10 g/kg) acı kırmızı biber ilave edilerek 1 günlük yaştan itibaren beslenen horozlarda büyüme ve reprodüktif organlarda yapısal farklılıklar incelendi. Deney grubunda kilo almanın azaldığı, testislerde ağırlık, en, boy ve tubulus seminiferus kontortus duvar kalınlığı ölçülerinin arttığı, spermatogenik hücre serisinin kontrol grubuna göre daha erken tamamlandığı görüldü.

Anahtar Sözcükler: Acı kırmızı biber, horoz, reprodüktif organlar

Introduction

Red hot pepper is a spice consumed as condiment with food, mostly in the south Anatolian region of Turkey. Red hot pepper is the ripened fruit of pepper plant. It is a member of the family Solanaceae and its Latin name is *Capsicum annum*. It consists of 6%-7% glucose, 0.12%-35% carotenoids, nicotinic acid, iron, phosphorus, calcium, protein, water, and vitamins A, C and E. The active material capsaicin (C₁₈H₂₇N₃O₃), causing the hotness, is an odourless white alkaloid soluble in hot water, ethyl and methyl alcohols and acetone (1).

Information about red hot pepper is available from ancient sources. Mayans and Aztecs used it for toothache and for treatment of some diseases. It was reported that 2 drops of red hot pepper extract cured toothache and sore throat (2). Capsaicin is an effective topical analgesic for arthritis pain. Capsaicin creams are sold at health and

drug stores in the USA, Colombia, Mexico, Australia and Israel. In Turkey, red hot pepper is also used by layer and broiler chicken producers for various purposes, such as for darkening the colour of the yolk, and for sharpening the chick's appetite, which in turn causes weight gain or increases the rate of laying.

Widespread cell infiltration and necroses were observed in the livers of mice whose drinking water was supplemented with red hot pepper (3). Vardar et al. (3) pointed out that when small doses were used at intervals the toxic effects might decrease. Oktay and Olgun (4) fed adult hens by adding 0.4% red hot pepper to their diet. They observed that the colour of the yolk got darker but the productivity of the eggs, feeding behaviour and productivity of incubation were not affected. Vardar (5) stated that red hot pepper caused acute destruction in relation to an increased dose in the livers and kidneys of mice.

Capsaicin has been used in many studies. In these studies, the experiment group animals have generally been adults and doses of the capsaicin have varied. Adult hens fed red hot pepper added to their diet had darker egg yolks, and the laying rate was 80.5% in the experiment group whereas it was 79.3% in the control group (6). Furuse et al. (7) reported that there was no difference in the quantity of abdominal fat content among adult laying hens fed with red hot pepper added to their diet while the egg performance increased 3%. Özer et al. (8) stated that follicular development in the ovaria of laying hens fed red hot pepper added to their diet (1%) was faster and laying started 11 days before it did in the control group. Traurig et al. (9) reported that capsaicin-treated rats in the postnatal period had retarded body development. Nopanitaya (10) stated that rats' body growth was retarded when they were fed a diet containing capsaicin. Escott and Brain (11) stated that rats that received local applications of capsaicin on the skin had increased blood flow on their body surface.

The present study aimed to examine whether a diet containing red hot pepper in low doses would cause any development differences in the reproductive system organs of cocks from 1 day of age to 5 months of age.

Materials and Methods

This research started with 200 one-day-old Isobrown male chicks and lasted for 5 months (between February and June). One hundred chicks, which formed the control group, were fed a ration prepared according to the chick development diet (Table 1). The other 100 chicks, which formed the experiment group, were fed the same ratio, to which 1% red hot pepper (powder) grown in the Kahramanmaraş region was added. Both groups were kept in the same environmental conditions.

The study was carried out over 5 months. At the end of each month, 10 chicks from both control and experiment groups were chosen at random to determine their body weight gains. Then they were sacrificed under deep anaesthesia and their testes and epididymides were removed and weighed. The lengths and widths of testes were measured. For histological examinations, tissue pieces taken from testes randomly were separately fixed in tamponated formalin, Bouin's, or ca-formalin solutions. Then 5-µm thick sections obtained from the paraffin-embedded tissue pieces were stained with the

Table 1. Composition and nutrients content of chick development diet.

INGREDIENTS AND COMPOSITION	%
Yellow corn	59.50
Soybean meal (44%)	9.60
Sunflower meal	13.40
Fish meal	0.80
Meat-bone meal	2.50
Full fat soybean	4.70
Limestone	8.40
Dicalcium phosphate	0.40
Salt	0.26
Mineral Premix 1	0.10
Vitamin Premix 2	0.25
Methionine	0.04
ANALYSED VALUES	%
Dry matter	88
Crude ash	13
Crude protein	15
Ether extract	3.30
Crude fibre	6.2

Mineral premix provided the following per kilogram of diet 1: Mn: 80,000 mg, Fe: 35,000 mg, Zn: 50,000 mg, Cu: 5000 mg, I: 2000 mg, Co: 400 mg, Se: 150 mg.

Vitamin premix provided the following per 2.5 kilograms of diet 2: Vit A: 1,200,000 IU, Vit D3: 2,000,000 IU, Vit E: 30,000 mg, Vit K3: 3000 mg, Vit B1: 3000 mg, Vit B2: 6000 mg, Vit B6: 5000 mg, Vit B12: 15 mg, Niacin: 25,000 mg, Biotin: 40 mg, Carotenoid: 8000 mg, Folic acid: 1000 mg, Choline chloride: 300,000 mg, Vit C: 50,000 mg.

triple stain method of Crossmonn's modification (12). The Periodic Acid Schiff (PAS) stain method (13) was used to determine the glycogen and glycoprotein contents, and the Oil-Red-O method (14) to determine lipid accumulation. During the experiment, the wall thickness of the tubuli seminiferi convoluti of the control and experiment group testes was measured with the help of an ocular graticule (µm) in 20 samples at the end of each month. The data obtained from the measures and weights were determined histometrically and compared using Student's t-test (15).

Results

At the end of the first month of the study, 10 chicks from both the control and experiment group were chosen

randomly to determine average body weights, and testes weights, lengths and widths (Table 2). Some of the interstitial cells (Leydig cells) had unstainable vacuoles in the space between seminiferous tubules. It was observed that the spermatogenic cells formed a layer of 1-2 cell lines and between these cells there were Sertoli cells in the seminiferous tubules wall. The average width of this layer was shown (Table 2). Spermatogonia were in the majority in this layer of control group testes (Figure 1), whereas primary spermatocytes with large and euchromatic nuclei were seen between and above the spermatogonia in the experiment group (Figure 2). A light positive reaction was observed in some interstitial

cells stained with the Oil-Red-O method in the control group. In contrast, a positive reaction was more commonly diffused and widespread in the experiment group than in the control group. A positive reaction with PAS staining was observed only in the connective tissue surrounding the seminiferous tubules of both control and experiment group testes.

At the end of the second month of the study, body weights and testes measures of both the control and experiment groups were not statistically different, with the exception of the seminiferous epithelial thickness (Table 2). Interstitial spaces between the seminiferous tubules were smaller compared to those in the first

Table 2. Morphological values between control and experiment group cocks from 1 month to 5 months of age. Results expressed as mean \pm SE.

	n	1 st month		2 th month		3 th month		4 th month		5 th month	
		control x \pm Sx	experiment x \pm Sx	control x \pm Sx	experiment x \pm Sx	control x \pm Sx	experiment x \pm Sx	control x \pm Sx	experiment x \pm Sx	control x \pm Sx	experiment x \pm Sx
Body weight (g)	10	210 \pm 2.91	210 \pm 2.24	751.2 \pm 4.77	769 \pm 16.7	1311 \pm 28.21	1273 \pm 30.04	1573 \pm 35.01	1468 \pm 17.31	1700 \pm 27.9	1589 \pm 16.85
Testis weight (g)	10	0.05 \pm 0.004	0.044 \pm 0.005	0.22 \pm 0.015	0.23 \pm 0.018	2.93 \pm 0.64	2.66 \pm 0.84	8.10 \pm 0.64	9.25 \pm 0.66	9.61 \pm 0.28	12.37 \pm 0.69
Testis length (g)	10	7.1 \pm 0.23	7.2 \pm 0.32	12.10 \pm 0.43	11.2 \pm 0.24	24.40 \pm 2.6	25.40 \pm 2.1	37.6 \pm 1.21	39.1 \pm 0.77	40.70 \pm 0.54	44.9 \pm 1.52
Testis width (mm)	10	3.1 \pm 0.23	2.6 \pm 0.16	4.80 \pm 0.20	5.30 \pm 0.33	12.50 \pm 1.67	12.90 \pm 1.31	19.7 \pm 0.58	21.2 \pm 0.55	21.4 \pm 0.34	24 \pm 0.73
Semi. Canal epit. thickness (μ)	10	16.28 \pm 1.12	19.86 \pm 0.62	21.52 \pm 0.61	22.9 \pm 0.19	41.13 \pm 3.41	50.57 \pm 5.09	57.8 \pm 1.27	62.56 \pm 1.89	57.9 \pm 0.59	70.74 \pm 4.38

Differences between months and control and experiment groups within each month are statistically significant (*P < 0.05, **P < 0.01, ***P < 0.001).

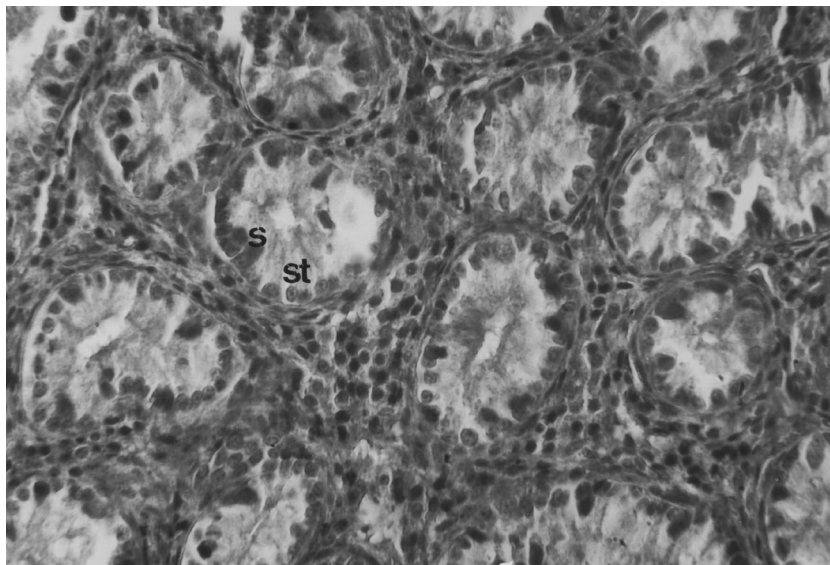


Figure 1. Sertoli cells (s), spermatogonia (st), at the end of the first month in the control group. X800

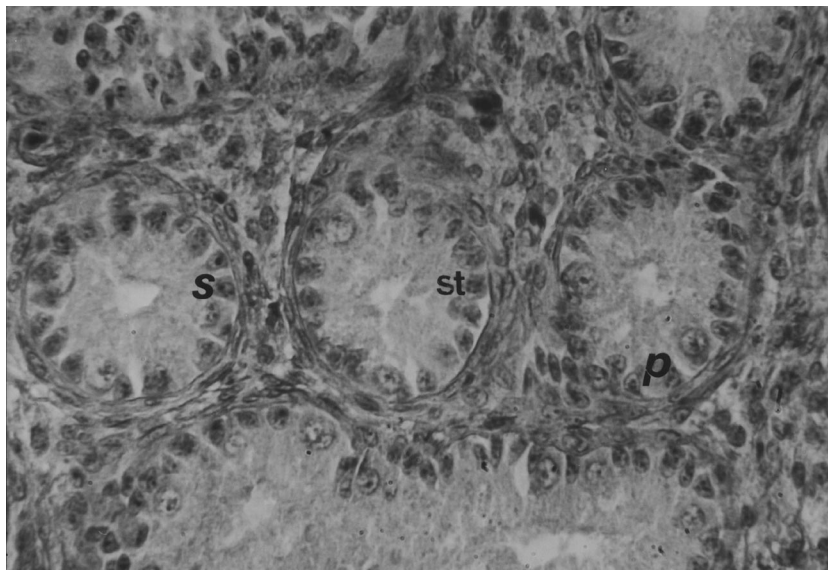


Figure 2. Sertoli cells (s), spermatogonia (st) and primary spermatocyte (p) at the end of the first month in the experiment group. X800

month in the control group testes. In these spaces, acidophilic cells were seen together with numerous unstained cells. The wall of the seminiferous tubules contains 2 spermatogenic cell lines. In the first line, there were spermatogonia and Sertoli cells. In the second line, there were primary spermatocytes located between spermatogonia and the upper line. Reduction of the interstitial space and numerous unstained cells were observed in the experiment group. Reactive lipid cells and unreactive vacuolar cells were seen in the interstitial space of the control group testes stained with the Oil-Red-O method, whereas there were numerous reactive lipid cells and unreactive vacuolar cells in the interstitial space of experiment group testes stained with the Oil-Red-O method. The data obtained by PAS staining were similar to those in the first month in control and experiment groups testes.

At the end of the third month of the study, body weights and testes measures of both control and experiment groups did not differ significantly (Table 2). Primary spermatocytes 2 or 3 cell lines were seen in the upper part of the spermatogonia on the wall of the seminiferous tubules in the control group testes. At this stage, Sertoli cells were easily distinguished with their euchromatic and oval nucleus (Figure 3). Primary, secondary spermatocytes and spermatids 2 or 3 cell lines near the lumen were observed in the seminiferous tubule

wall of the experiment group testes. A few spermatozoa in the seminiferous tubule lumen were seen. At this stage, Sertoli cells became known with spermatids at the maturation phase in their cytoplasm (Figure 4). Reactive lipid cells were dense at the corner of neighbouring seminiferous tubules stained with the Oil-Red-O method in the control group testes. A few large unreactive vacuolar cells were located between lipid cells. A strong and widespread positive reaction stained with the Oil-Red-O method was seen in the lipid cells surrounding the seminiferous tubules of testes in the experiment group. At this stage, residual bodies and spermatids in the last period of the maturation phase in epididymal canal lumens of the control group testes were seen (Figure 5), whereas numerous mature spermatozoa were seen in the lumens of the epididymis in the experiment group testes (Figure 6).

At the end of the fourth month of the study, body weights and testes measures of control and experiment group cocks were not significantly different except for the differences in body weight gain and seminiferous tubules epithelial thickness (Table 2). Decreased numbers of interstitial cells (Leydig cells) were seen in the interstitial space in both control and experiment group testes. It was observed that the differentiation of the spermatocytogenic cell cycle had been completed in the wall of the seminiferous tubules in the control group

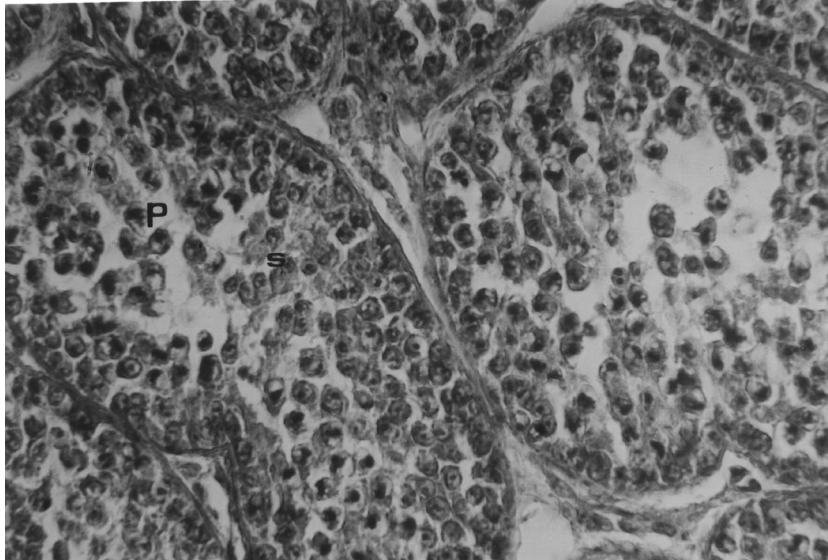


Figure 3. Primary spermatocytes (p), secondary spermatocytes (s) at the end of the third month in the control group. X1000

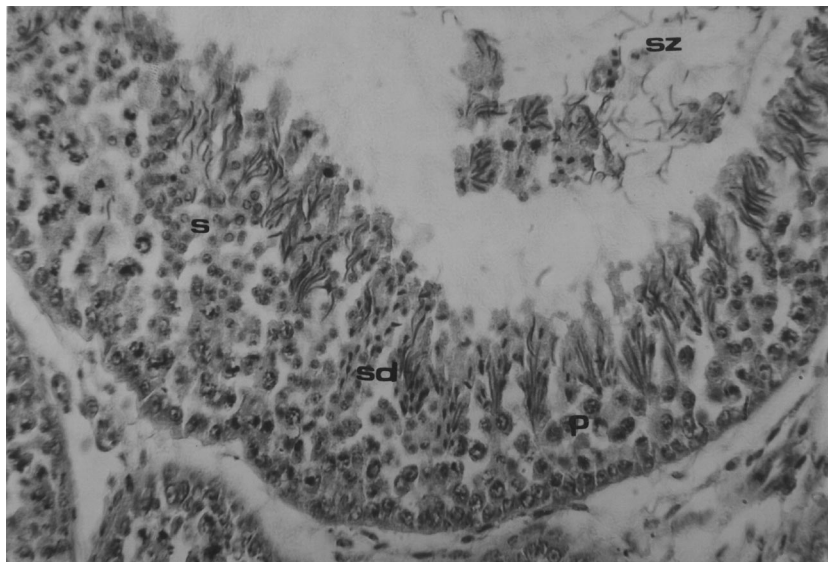


Figure 4. Primary spermatocytes (p), secondary spermatocytes (s), spermatids (sd) and spermatozoa (sz) at the end of the third month in the experiment group. X800

testes. At this stage Sertoli cells became known with spermatids in their cytoplasm near the lumen at the maturation phase in the wall of the seminiferous tubules (Figure 7). In the experiment group spermatocytogenic cell differentiation was completed and production of spermatozoa continued in the tubuli seminiferi convoluti of testes. It was observed that secondary spermatocytes

and spermatids formed 4 or 5 cell lines near the lumen of seminiferous tubules in the experiment group testes. At this stage Sertoli cell cytoplasm was full of spermatids from the basal part to the lumen of the seminiferous tubules (Figure 8). It was seen that the positive reaction stained with the Oil-Red-O method was slight in the interstitial tissue of both the control and experiment

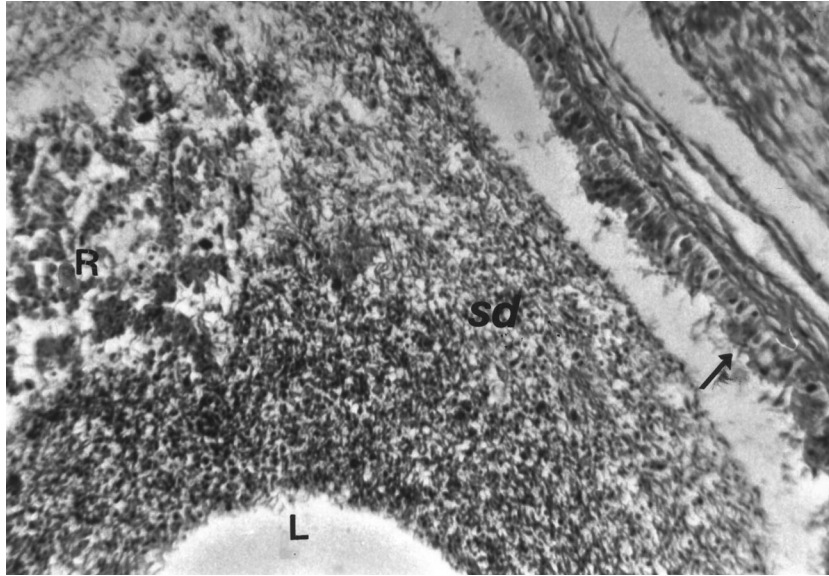


Figure 5. Lumen of the epididymal canal (L), residual body (R), spermatids (sd) and phagocytosed spermatozoa (arrow) at the end of the third month in the control group. X400

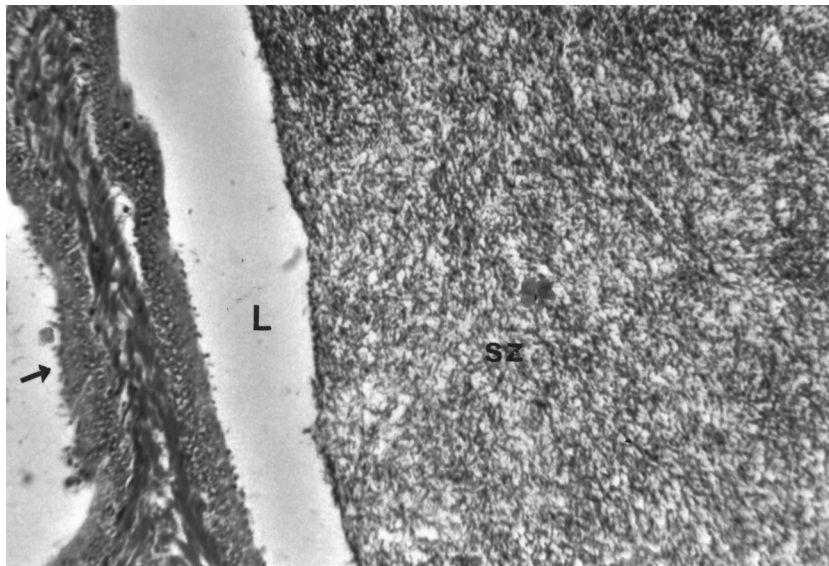


Figure 6. Lumen of the epididymal canal (L), spermatozoa (sz) and phagocytosed spermatozoa (arrow) at the end of the third month in the experiment group. X400

group testes. The ductus epididymises had similar structural aspects in the control and experiment group testes.

At the end of the fifth month of the study, body weights and testes measures of both control and experiment group cocks were significantly different

(Table 2). The number of interstitial cells (Leydig cells) in both the control and experiment group testes decreased. Spermatocytogenic cell cycles were completed and the production of spermatozoa continued in the control group testes. Spermatids were seen in the apical part of the Sertoli cells' cytoplasm. Residual bodies, spermatozoa

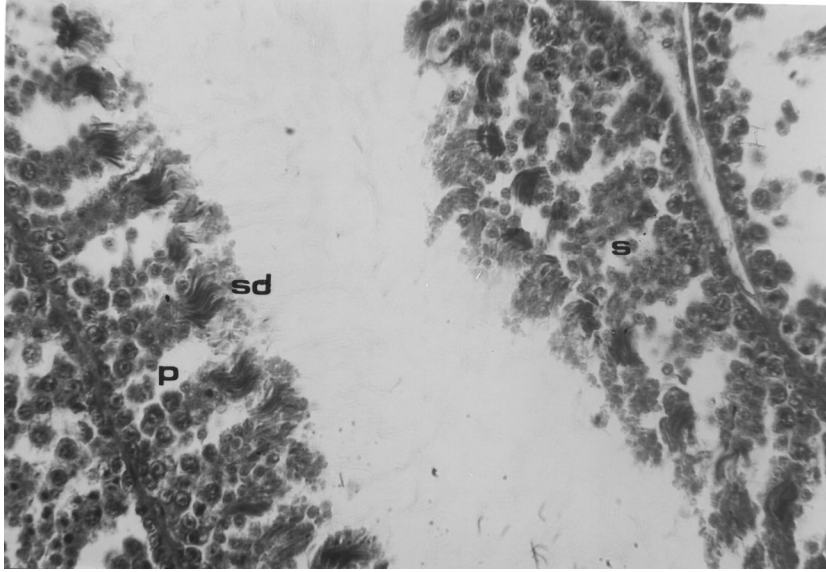


Figure 7. Primary spermatocytes (p), secondary spermatocytes (s), spermatids (sd) and spermatozoa (sz) in the wall of the seminiferous tubules at the end of the fourth month in the control group. X800

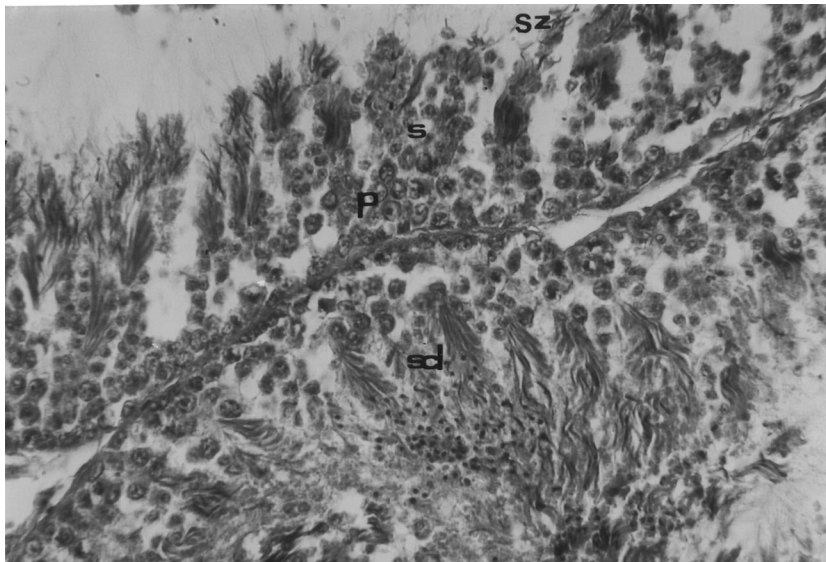


Figure 8. Primary spermatocytes (p), secondary spermatocytes (s), spermatids (sd) and spermatozoa (sz) in the wall of the seminiferous tubules at the end of the fourth month in the experiment group. X800

and degenerated cells were seen in the lumen of the seminiferous tubules. The production of spermatozoa continued in the experiment group testes. The population of cells in the wall of the seminiferous tubules varied in the control group testes. In this cell layer, secondary

spermatocytes and spermatids dominated. Sertoli cell cytoplasm was full of spermatozoa. Spermatids, residual bodies, spermatozoa and degenerated cells were located in the lumen of the seminiferous tubules. The positive reaction stained with the Oil-Red-O method was slight in

the interstitial cells of both the control and experiment group testes. A positive reaction stained with PAS was observed only in the connective tissue surrounding the seminiferous tubules of both control and experiment group testes. The ductus epididymis had similar structural aspects in control and experiment group testes.

Discussion

In the present study, the increase in body weight was high except in the second month in the control group chickens. The findings were in agreement with the results reported by some researchers (3,8,11,16-20). These researchers pointed out that capsaicin affected lipid metabolism negatively and slowed down body growth gain.

Some data such as weight, length and width of testes showed an increase in the experiment group testes. In a histological textbook (18) it was reported that the length of the adult cock testes was 1.5-4.5 cm and width was 0.7-1.7 cm. Our findings obtained from the fifth month of this study showed that the average lengths of the testes were similar and the average testes widths were greater than those in the textbook.

In some histological textbooks (17,18) researchers stated that there was areolar connective tissue between the tubuli seminiferi of testes and this tissue contained cell communities. These cell communities contained Leydig cells, peritubular cells, blood vessels, lymphatics and nerves. The tubuli seminiferi convoluti was surrounded by a thin connective tissue layer. In the present study, the testes of the control and experiment group cocks showed similar structural aspects to the results in the textbooks.

Interstitial tissue is limited in mature testes. Large numbers of melanoblasts may also be located in this tissue in some avian species. Interstitial cells (Leydig cells), which are functional cells of this tissue, are

scattered between the tubuli seminiferi convoluti either individually or in small groups (17,18). Leydig cells are divided into 2 types: lipid cells and secretory cells. Lipoid cells are Sudan-positive and give a positive reaction to cholesterol tests. Secretory cells, characterised by the presence of numerous mitochondria, have 2 basic types, which are divided into 2 subtypes: type A without vacuoles and type B with a single and large vacuole. In the mature male testes the relative proportions of these cell types are as follows: lipid cells type A approximately 20%, secretory cells type B approximately 30%. The source of male hormone (testosterone) is considered to be the secretory cells (18). Lipoid cells undergo seasonal differences. Lipoid cells, which are full of cholesterol in the autumn, discharge lipid materials and become fuchsinophilic in the spring (17). Aire (16) states that, in some avian species (such as the cock, duck, and Japanese quail) that have inactive gonad aspects, Leydig cells are full of lipid droplets of heterogeneous bodies and lysosomes; thus they resemble the degenerated cells. The present study was carried out between February and June. Leydig cells in the interstitial tissue were seen as reaction positive cell type and negative cell type stained with the Oil-Red-O method in control and experiment group testes. Reaction positive lipid cells were numerous at the end of the third month (April). At the end of the fifth month, when the fertilisation performance was supposed to be at the highest level, the number of lipid cells decreased and therefore the number of vacuolated cells increased. These results showed that the production of testosterone hormone began at end of the third month. Cockerels were ready for fertilisation at the fourth and fifth months of the experiment, as a result of the decreased number of lipid cells and the increased number of vacuolated cells in their testes.

In conclusion, red hot pepper added to the cock diet in low doses during the developing period (5 months) could decrease body weight gain, but it could stimulate the development of the reproductive organs.

References

1. Schormüller, J.: Alkaloidhaltige Genussmittel, Berlin, Heidelberg, Gewürze, Kochsals Gewürze, Kochsals Springer- Verlag. 532-538. 1970.
2. Boyunağa, H., Çelik, C.: Kırmızı acı biber (capsaicin) bitkisel ilaç kaynağı mı? Bilim Teknik Tübitak, 1995; 6: 331.
3. Vardar, K.T., Hatipoğlu, M.T., Çimen, A.: Güneydoğu Anadolu bölgesinde gıda additifi olarak kullanılan bazı toz biberlerin hepatotoksik etkisi ile ilgili bir araştırma. Ankara Üniv. Diyarbakır Tıp Fak. Derg., 1972; 1: 399-408.
4. Oktay, E., Olgun, H.: Kırmızı biberin New Hampshire tavuklarında yumurta verimi, yumurta kalitesi ve kuluçka verimine etkisi. Ankara IV. Bilim Kongresi. 1973.

5. Vardar, K.T.: Urfa orijinli kırmızı pul biberlerin toksik etkisi üzerine bir araştırma. Diyarbakır Tıp Fak. Derg., 1974; 2: 33-36.
6. Hamilton, P.B., Tirado, F.J., Garcia-Hernandez, F.: Deposition in egg yolks of the carotenoids from saponified and unsaponified oleoresin of red pepper (*Capsicum annum*) fed to laying hens. Poul. Sci., 1990; 69: 462-470.
7. Furuse, M., Nakajima, S., Miyagawa, S., Nakagawa, J., Okumura, J.: Feeding behaviour, abdominal fat and laying performance in laying hens given diets containing red pepper. Jap. Poul. Sci., 1994; 31: 45-52.
8. Özer, A., Erdost, H., Zik, B.: Histological investigations on the effects of feeding a diet containing red hot pepper on the reproductive organs of the chicken. Journal Phytother. Res., 2005; 19: 501-505.
9. Traurig, H., Saria, A., Lembeck, F.: The effect of neonatal capsaicin treatment on growth and subsequent reproductive function in the rat. Naunyn Schmiedebergs Arch. Pharmacol., 1984; 327: 254-259.
10. Nopanitaya, W.: Long term effects of capsaicin on fat absorption and the growth of the rat. Growth, 1973; 37: 269-279.
11. Escott, K.J., Brain, S.D.: Effect of calcitonin gene-related peptide antagonist (CGRP8-37) on skin vasodilatation and oedema induced by stimulation of rat saphenous nerve. Br. J. Pharmacol., 1993; 110: 772-776.
12. Crossmonn, G.A.: Modification of Mallory's connective tissue stain with a discussion of the principles involved. Anat. Rec., 1937; 69: 33-38.
13. Lee, G., Luna, H.T.: Manual of Histological Staining Methods of the Armed Forces Institute of Pathology. McGraw-Hill Book Company. United States of America; 158-159. 1968.
14. Gimstone, A.V., Skaer, R.J.: A Guide Book to Microscopical Methods, Cambridge University Press: London. 53-54. 1972.
15. Sümbüloğlu, K., Sümbüloğlu, U.: Biyoistatistik, Ankara, Özdemir Yayıncılık, 145-148. 1994.
16. Aire, T.A.: The structure of the interstitial tissue of the active and resting avian testis. Onderstepoort J. Vet. Res., 1997; 64: 291-299.
17. Catherina, C.P., Arthur Cleegg, G.: Biology of the Mammal. Vol. III, Hong Kong, William Heinemann Medical Books Ltd. 519 - 573. 1975.
18. Hodges, R.D.: The Histology of the Fowl. Academic Press: London; 300-325. 1974.
19. Reddy, A.C., Lokesh, B.R.: Studies on spice principles as antioxidants in the inhibition of lipid peroxidation of rat liver microsomes. Mol. Cell. Biochem., 1992; 111: 117-124.
20. Srinivasan, M.R., Satyanarayana, M.N.: Effect of capsaicin on skeletal muscle lipoprotein lipase in rats fed high fat diet. Indian J. Exp. Biol., 1989; 27: 910-912.