

# Complications of 1303 central venous cannulations

A Yilmazlar MD H Bilgin MD G Korfali MD A Eren MD U Özkan MD

*J R Soc Med* 1997;90:319-321

## SUMMARY

**Central venous catheterization (CVC), now a common procedure, has several major complications. We assessed their incidence in a prospective study of 1303 cannulations done in the intensive care unit or operating theatre. Chest radiographs were obtained to verify proper catheter placement and to detect pneumothorax.**

**Complications were arterial puncture in 68 (5.2%) patients, arrhythmias in 21 (1.6%), cardiopulmonary arrest in 1 (0.1%), and pneumothorax in 5 (0.5%). The tip of the CVC was incorrectly located in 149 (11.2%).**

**The chest radiograph was a valuable method for detecting complications of central venous catheterization.**

## INTRODUCTION

Catheterization of central veins has become an important manoeuvre for measuring central venous pressure, infusing fluids and providing long-term intravenous nutrition. The four veins commonly used are the brachial, subclavian, external jugular, and internal jugular<sup>1,2</sup>. Of the major complications of this procedure, pneumothorax is the most common<sup>3-5</sup>. Here we report a prospective study of 1303 central venous catheterizations (CVC) done over 32 months, with emphasis on the complications.

## METHODS

Data were collected on all patients who had CVCs placed in the operating room or intensive care unit. Catheters were inserted by experienced residents and fellows, who first inserted a peripheral cannula. The patient was monitored electrocardiographically. Central venous catheters and introducers were made of polyurethane. The site of cannulation depended on clinical circumstances and the physician's preference.

For initial placement of catheters, the site was prepared with povidone solution and the patient was covered with sterile drapes; operators wore sterile gloves. Either single or triple lumen catheters were inserted by Seldinger or catheter through the needle technique. Single lumen catheters were either 16 or 18 FG (Cavafix, Braun); triple lumen catheters were 5.5 or 7 FG (Abbott, Medcomp). The number of attempts and the complications were recorded.

Postero-anterior chest radiographs were obtained on all patients after placement of catheters to verify proper catheter placement and identify complications. The anaesthetist who

inserted the catheter assessed the radiograph. The second right intercostal space was accepted as proper localization of the tip of the catheter. The results were recorded on a special form (three of which were excluded from analysis because of errors or incompleteness).

## RESULTS

1303 central venous catheters were placed during the study period, of which 568 were single lumen and 735 were triple lumen. Table 1 shows the veins employed for introduction.

Catheters were placed as desired on the first attempt in 952 (73.2%) patients, second attempt in 220 (16.9%), third attempt in 98 (7.5%), and fourth attempt in 30 (2.4%). Complications related to insertion included arterial puncture in 68(5.2%), arrhythmias (all ventricular extra-systole) in 21(1.6%), and one cardiac arrest.

On the post-insertion chest radiographs, complications were seen in 154 (11.5%) patients. The tip was incorrectly

Table 1 Route of catheterization

	No.	%
Right internal jugular vein	770	59.3
Right brachial vein	183	14.0
Left internal jugular vein	113	8.6
Left brachial vein	83	6.4
Right external jugular vein	73	5.6
Right subclavian vein	54	4.2
Left external jugular vein	14	1.1
Left subclavian vein	10	0.8
Total	1300	100

Data on 3 patients excluded

Department of Anaesthesiology, Uludağ University School of Medicine, Görükle, Bursa, Turkey

Correspondence to: Dr Gülsen Korfali

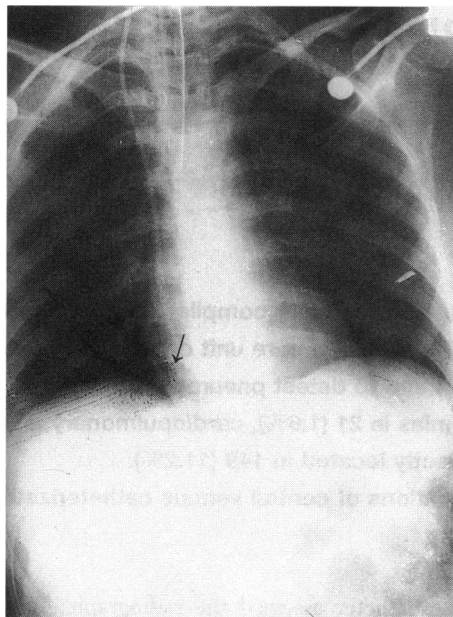


Figure 1 Tip of catheter (arrow) in right ventricle

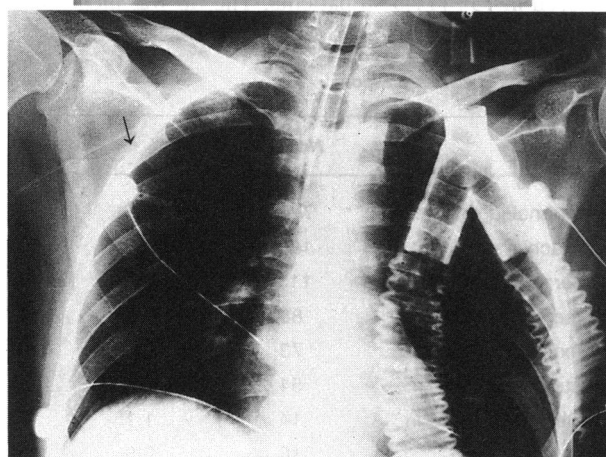
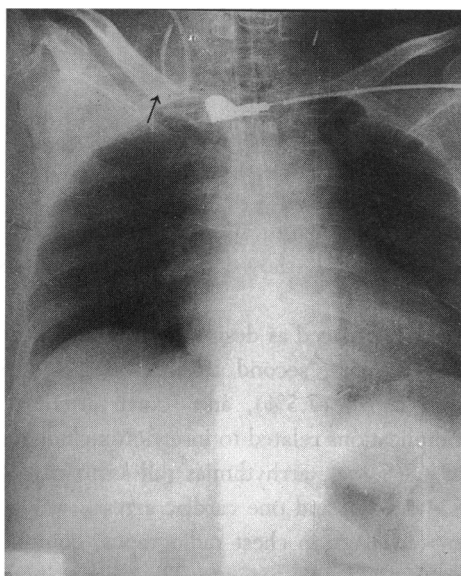


Figure 2 (a) Tip of the catheter (arrow) in the external jugular vein; (b) tip of catheter (arrow) in the internal jugular vein

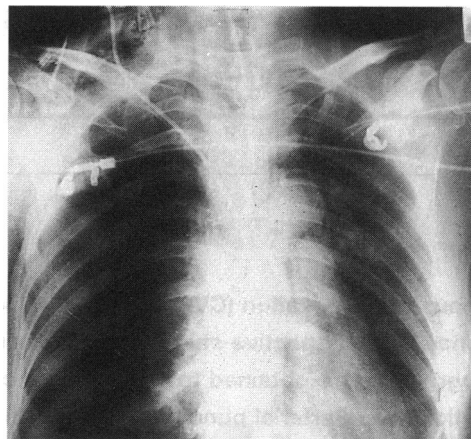


Figure 3 Right pneumothorax

located in 149 (11.2%), being in the right ventricle in 117, turned over in the right atrium in 18 and in the external or internal jugular vein in 14 (Figure 1a, b).

The internal jugular veins and the subclavian veins were used for 950 CVCs. Pneumothorax developed in 5 patients of this group (0.5%) (Figure 2). 4 of these complications occurred after internal jugular vein cannulation and 1 after subclavian vein cannulation.

Cardiovascular surgeons managed the pneumothoraces by thoracic intubation. Arterial puncture was treated by application of external pressure on the artery for 3–4 min. 1 mg/kg intravenous lignocaine was given for ventricular arrhythmias. The patient with cardiac arrest was resuscitated. All malpositioned catheters were corrected.

### DISCUSSION

The two veins commonly used for placement of central lines are the internal jugular vein and the brachial vein; in our practice catheters commonly are single and triple lumen. Failed attempts were associated with an increased likelihood of complications: 952 patients in whom catheterization was successful did not have any complications, compared with 95 (27.2%) of the 348 patients in whom physicians were unable to place catheters.

The results of this clinical study are in accordance with those obtained by Mansfield *et al.*<sup>6</sup> The rate of complications of CVC insertion has been reported between 2.3 and 11%<sup>7</sup> and the proportion in our series was 6.9%.

Arterial injury during CVC was reported in 4.1% by Lux<sup>4</sup> and 11.3% by Hayashi *et al.*<sup>8</sup>; in our study it was 5.2%.

Catheter malposition was reported in 1.9% by Hayashi *et al.*<sup>8</sup> and 5.2% by Tyburski<sup>9</sup>.

In our series the tip of the catheter was in the right ventricle in 8.9% and in the extra-cardiac veins in 1%.

Pneumothorax has been reported in 0–5.2% of CVCs<sup>4,5,8,9</sup>; our figure was 0.5%, and this low incidence

was due to the high proportion of internal jugular venous procedures, which carry less risk of pneumothorax than subclavian procedures. We did not observe any catheter-related complications such as fragmentation or knotting.

As noted earlier by Rutherford *et al.*<sup>10</sup>, the chest radiograph was a valuable way to detect complications.

## REFERENCES

- 1 Stoelting RK, Miller RD. *Basics of Anesthesia*, 2nd edn. New York: Churchill Livingstone, 1989:218–19
- 2 Kaplan JA. *Cardiac Anesthesia*, 3rd edn. Philadelphia: WB Saunders, 1993:42–88
- 3 Hagley MT, Martin G, Gast P, Traeger SM. Infectious and mechanical complications of central venous catheters placed by percutaneous venipuncture and over guidewires. *Crit Care Med* 1992;**20**:1426–30
- 4 Lux EA. Puncture catheterization of central veins—experiences from a primary care clinic. *Zentralbl Chir* 1992;**117**:427–31
- 5 Wey SB, Akamine N, Fernandes Junior C, Cendoroglo NM, Knobel E. Complications of central venous catheters: prospective study. *Rev Assoc Med Bras* 1993;**39**:88–90
- 6 Mansfield PF, Hohn DC, Fornage BD, Gregurich MA, Ota DM. Complications and failures of subclavian vein catheterization. *N Engl J Med* 1994;**331**:1735–8
- 7 Sitzmann JV, Townsend TR, Siler MC, Barlett JG. Septic and technical complications of central venous catheterization. *Ann Surg* 1985;**202**:766–70
- 8 Hayashi Y, Uchida O, Takaki O, Ohnishi Y, Nakajima T, Kataoka H, *et al.* Internal jugular vein catheterization in infants undergoing cardiovascular surgery: an analysis of the factors influencing successful catheterization. *Anesth Analg* 1992;**74**:688–93
- 9 Tyburski JG, Joseph AL, Thomas GA, Saxe JM, Lucas CE. Delayed pneumothorax after central venous access: a potential hazard. *Am Surg* 1993;**59**:587–9
- 10 Rutherford JS, Merry AF, Occleshaw CJ. Depth of central venous catheterization and audit of practice in a cardiac surgical unit. *Anaesth Intensive Care* 1994;**22**:267–71