

## Suspected Succinylcholine Poisoning in a German Shepherd Dog

Hasan Hüseyin Oruç<sup>\*1</sup>, Ahmet Akkoç<sup>2</sup>, Aylin Alasonyalılar<sup>2</sup>, Sami Aydın<sup>3</sup>

<sup>1</sup> Department of Pharmacology and Toxicology, Faculty of Veterinary Medicine, Uludag University, 16059 Gorukle Kampusu, Bursa, Turkey.

<sup>2</sup> Department of Pathology, Faculty of Veterinary Medicine, Uludag University, 16059 Gorukle Kampusu, Bursa, Turkey.

<sup>3</sup> Department of Pharmacology and Clinic Pharmacology, Faculty of Medicine, Uludag University, 16059 Gorukle Kampusu, Bursa, Turkey.

### ABSTRACT

This report describes succinylcholine poisoning observed in a 4-year-old male, German shepherd dog. The dog was referred to Faculty of Veterinary Medicine, Uludag University in Bursa, Turkey for necropsy and toxicological investigation in February of 2008. The dog has died after muscular contractions and salivation in short time. An automatic injector was found on the right distal abdominal of the dog before death. Examining appropriate historical and clinical signs, pathologic and histopathologic findings with the dog and discovery of succinylcholine in a drop residue found in the automatic injector supported a diagnosis of succinylcholine poisoning.

**Key Words:** Succinylcholine (suxamethonium), poisoning, dog, death, diagnosis, automatic injector .

### INTRODUCTION

Succinylcholine (SuCh) is a short-acting, depolarising, neuromuscular blocking agent that is used extensively in anaesthesia to achieve muscle relaxation (Larijani et al. 1991). SuCh induces loss of the electrical activity of the motor endplate, which resulted in paralysis (Spence and Maddison 2002).

Although SuCh has a rapid action, the duration of this action is short, because it is rapidly metabolised by plasma butyrylcholinesterase (pseudocholinesterase) into choline and succinylmonocholine (Durant and Katz 1982). SuCh is structurally similar to acetylcholine and is capable of stimulating nicotinic receptors in parasympathetic and sympathetic ganglia, as well as muscarinic receptors in the sinoatrial node of the heart. Consequently, various cardiovascular effects are possible, including bradycardia, tachycardia, hypotension and hypertension. Arrhythmias have also been reported in animals (Aiello 1998, Spence and Maddison 2002). These changes in heart rate may relate with elevated serum potassium level and stimulation of autonomic ganglia (Pugh 1991). In addition, SuCh can cause malignant hyperthermia (hyperpyrexia) in susceptible animals (Aiello 1998, Spence and Maddison 2002). The side effects of SuCh are associated with the initial depolarization, and consist of uncoordinated muscular contractions, salivation (Pugh 1991).

Intramuscular administration of large SuCh doses in animals causes prolonged paralysis of skeletal and respiratory muscles, leading to fatal hypoxic hypoxia (Upson 1980, De Vos et al. 1983, Pugh 1991). SuCh chloride can lead to deaths in horses due to central depression of respiration (Belling and Booth 1955).

Suspected death of the dog prompted us to investigate the causal agent responsible and necropsy findings. To the author's knowledge, although there are a few experimental studies (Nordgren et al. 1984, Baldwin and Forney 1988) concerning half-life, volume of distribution and clearance of SuCh in dogs, there is no published report on SuCh poisoning in dogs. Therefore, in this case, we aimed to describe SuCh poisoning with clinical, post-mortem and toxicological findings in the German shepherd dog.

### MATERIALS AND METHODS

#### *Case History*

A death German shepherd dog was referred to University of Uludag, Faculty of Veterinary Medicine on 11th February of 2008, Bursa, Turkey. The dog was 4-year-old male living in a factory garden as a guard dog. The dog owner had noticed the dog was freely resting just front of the factory in that morning on street. Suddenly, the dog entered to the factory as afraid of something, and then the dog had a short history of muscular contractions and salivation just before death, in short time.

---

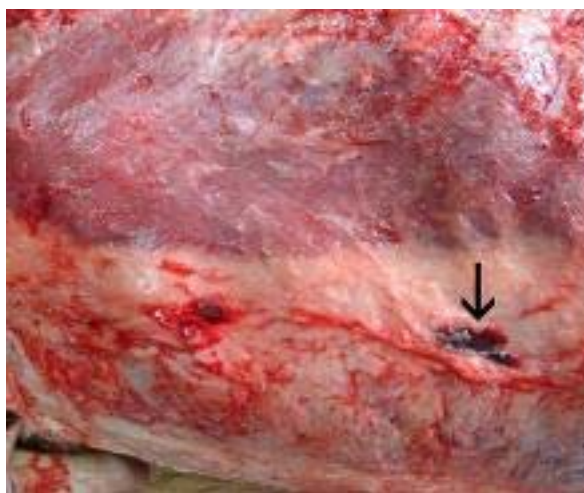
\* Corresponding author: oruc@uludag.edu.tr

### **Materials and methods**

An automatic injector was found on the right distal abdominal of dog before death and it stored at -20 °C for investigation. Tissue samples from liver, kidney, spleen, heart, lung, stomach, intestines and brain were fixed in 10% neutral-buffered formalin, paraffin-embedded and cut into 5 µm thick sections. All slides were stained with hematoxylin and eosin (H&E). We decided SuCh analysis in a drop residue in the automatic injector according to appropriate history, clinical signs and post-mortem findings. SuCh analysis was made in the sample using a liquid chromatographic system (Agilent, 1100 series, Waldronn, Germany) equipped with a BAS column (Bioanalytical Systems, West Lafayette, IN, USA). The mobile phase consists of 0.05 Na<sub>2</sub>HPO<sub>4</sub>, pH 8.5, and flow rate was 1ml /min. Detection was made by electrochemical detector (HP 1049A). The HPLC method used for SuCh analysis was column manufacturer's method (Bioanalytical Systems Incorporation 1990). SuCh chloride (Lysthenon, Fako, Turkey) was used as a SuCh standard.

### **RESULTS**

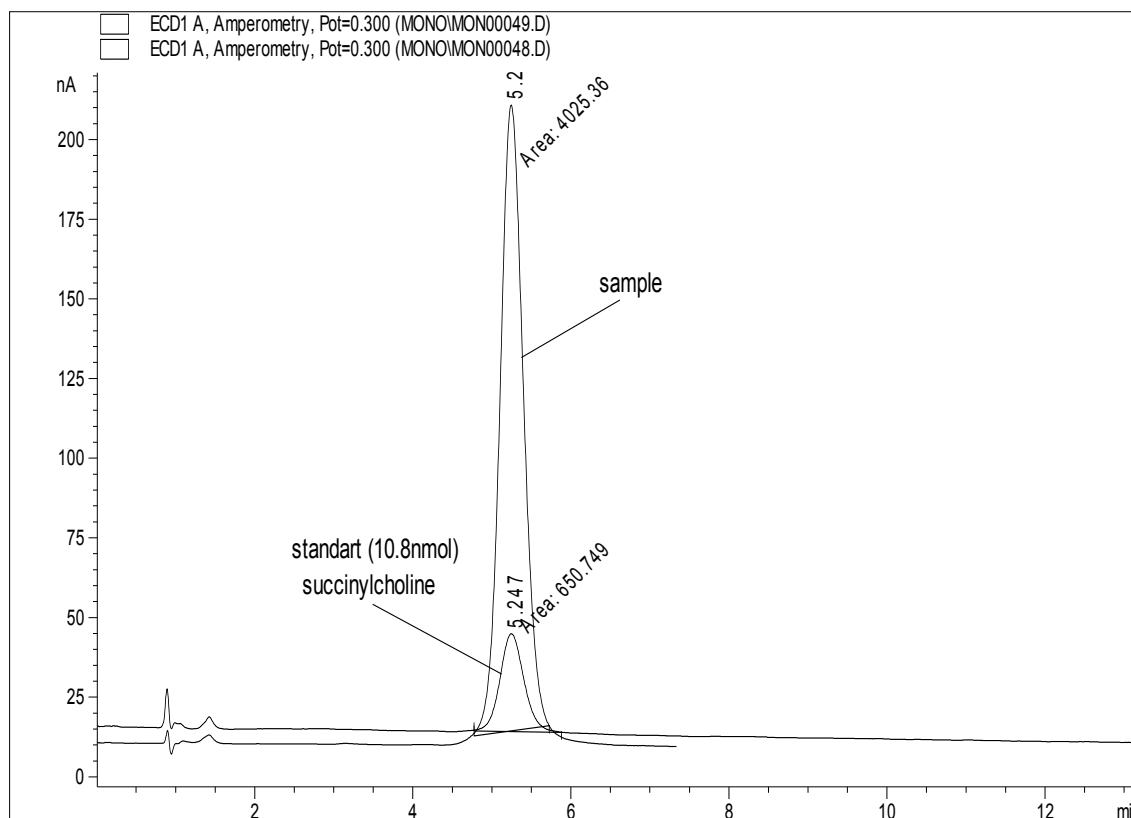
Macroscopically, bloody discharge-oozing from the nose and mouth the spot-pinpoint shaped subcutaneous haemorrhage located on the right distal abdominal muscles with 0.2 mm diameter (Figure 1). The lungs were severely hyperaemic and oedematous, in the lumen of trachea and primary bronchus reddish foam were observed. Bloody foam was oozing from the cut section of the all lung lobes. The liver and kidney were severely congested, and the pancreas had a hyperaemic appearance with a few whitish necrotic foci. Mesenterial and peritoneal blood vessels were dilated. In the examination of the skull, all meningeal and parenchymal blood vessels showed severe hyperaemia.



**Figure 1.** Focal subcutaneous haemorrhage in the right distal abdominal wall (arrow).

Microscopically, the liver sections revealed severe congestion and small necrotic foci together with inflammatory mononuclear cell infiltrations were found. In the examination of the lung sections, severe hyperaemia of the all vessels, alveolar oedema and haemorrhage were noticed. The meningeal and parenchymal blood vessels were filled with erythrocytes, and some of the neurons in the brain were necrotic (red neuron). In the other organs studied (spleen, kidney, heart, intestines, lymph nodes) no lesions were observed except the hyperaemia of the blood vessels.

SuCh was detected in a drop residue in the automatic injector as shown Figure 2.



**Figure 2.** Detected succinylcholine in the sample in automatic injector.

## DISCUSSION

SuCh can cause some side and toxic effects in animals. These effects are uncoordinated muscular contractions, salivation (Pugh 1991), various cardiovascular effects such as bradycardia, tachycardia and arrhythmias, malignant hyperthermia in susceptible animals (Aiello 1998, Spence and Maddison 2002), and prolonged paralysis of skeletal and respiratory muscles, leading to fatal hypoxic hypoxia (Belling and Booth 1955, Upson 1980, De Vos et al. 1983, Pugh 1991).

Clinically, muscular contractions and salivation in the dog prior to death are similar with findings related to SuCh poisoning reported by Pugh (1991). There are not sufficient clinical and especially pathological data related poisoning of SuCh in dogs. Particularly, necropsy and histopathological findings related to nose (bloody discharge-oozing), the lungs (severely hyperaemic and oedematous, in the lumen of trachea and primary bronchus reddish foam, bloody foam was oozing from the cut section of the all lung lobes and severe hyperaemia of the all vessels, alveolar oedema and haemorrhage) (Belling and Booth 1955, Upson 1980, De Vos et al. 1983, Pugh 1991) and effects on the vessels (Upson 1980) in this case attributed to SuCh poisoning. Additionally, the liver and kidney were severely congested, the pancreas had a hyperaemic appearance with a few whitish necrotic foci, all meningeal and parenchymal blood vessels showed severe hyperaemia and the meningeal and parenchymal blood vessels were filled with erythrocytes, and some of the neurons in the brain were necrotic (red neuron). SuCh was determined in sample in the automatic injector. SuCh should be used in the dog for euthanasia or immobilization in this case by pistol-type projector with automatic injector since SuCh might be used for immobilization for stray dogs. SuCh analysis in blood and some tissues is also important for diagnosis of SuCh poisoning. However, SuCh analysis in the samples of dead dog could not be completed since SuCh poisoning was not suspected during sampling time.

In this case, appropriate history and clinical signs, post-mortem findings and demonstration of SuCh in the sample in automatic injector found on the abdominal of dog support a diagnosis of SuCh poisoning.

## REFERENCES

- Aiello SE (1998): Neuromuscular Blocking Agents, Depolarizing Agents. The Merck Veterinary Manual. Merck&Co Inc, Whitehouse Station, pp. 1709-1712.
- Baldwin KA, and Forney RJr (1988). Correlation of plasma concentration and effects of succinylcholine in dogs. *J. Forensic Sci.*, 33(2):462-469.
- Belling TH, and Booth NH (1955). Studies on the pharmacodynamics of succinylchloride in the horse. *JAVMA*, 126: 37-42.
- Bioanalytical Systems Incorporation (1990). User manual for acetylcholine, choline, assay kit, kit p/n: MF-8910, manual p/n: MF-9053. West Lafayette, pp. 1-18.
- De Vos V, Bengis RG, and Coetzee HJ (1983). Population control of large mammals in the Kruger National Park. In: Management of Large Mammals in African Conservation Areas, (Eds.: R.N. Owen-Smith). HAUM Educational Publishers, Pretoria, pp. 213-231.
- Durant NN, and Katz RL (1982). Suxamethonium. *British J. Anaest.*, 54:195-208.
- Larijani GE, Gratz I, Silverberg M, and Jacobi AG (1991). Clinical pharmacology of the neuromuscular blocking agents. *DICP Ann. Pharmacother.*, 25: 54-64.
- Nordgren I, Baldwin KA, and Forney RJr (1984). Succinylcholine-tissue distribution and elimination from plasma in the dog. *Biochem. Pharmacol.*, 33(15): 2519-2521.
- Pugh DM (1991). Depolarizing blocking agents. In: *Veterinary Applied Pharmacology&Therapeutics*, (Eds.: G.C. Brander, D.M. Pugh, R.J. Bywater and W.L. Jenkins). Baillière Tindall, London, pp. 94-96.
- Spence I, and Maddison JE (2002). Depolarizing Muscle Relaxants. In: *Small Animal Clinical Pharmacology*, (Eds.: J.E. Maddison, S. Page and D. Church). W.B. Saunders, London, pp. 64-65.
- Upson DW (1980). Suggestions for the use of succinylcholine chloride. *Upson's Handbook of Clinical Veterinary Pharmacology*. VM Publishing, Kansas, pp. 256-257.