

Cutaneous Lesions Associated with Reo-like Virus in a Green Lizard (*Lacerta viridis* LAURENTI 1768)

İsmail Hakkı Uğurtaş¹, Musa Özgür Özyiğit^{2*}, Ahmet Akkoç²,
Gerry M. Dorrestein³ and Abdulmüttalip Akkaya¹

¹ Department of Biology, Faculty of Arts and Sciences, Uludag University, Görükle, 16059, Bursa, Turkey

² Department of Pathology, Faculty of Veterinary Medicine, Uludag University, Görükle, 16059, Bursa, Turkey

³ Department of Pathology, Faculty of Veterinary Medicine, Utrecht University, Utrecht, Netherlands

ABSTRACT

In this case, a green lizard (*Lacerta viridis* LAURENTI 1768) caught in Uludag, Bursa, north-western Turkey, was diagnosed as reovirus by electron microscopy. In the macroscopical examination, wart-like growths were seen on the dorsum of the animal on the skin between the forearms and on the back close to the pelvic region. In the microscopical examination of hematoxylin and eosin stained sections, hyperkeratosis, ballooning degeneration and eosinophilic inclusions in the cytoplasm were observed. There was no positive reaction for papillomavirus in immunohistochemistry. Electron microscopic study of these growths revealed the presence of viral particles belonging, from the morphological aspect, to the family *Reoviridae*.

Key Words: Green lizard, *Lacerta viridis*, reovirus, papilloma.

INTRODUCTION

The family *Reoviridae* represents a large and diverse group of non-enveloped viruses (Duncan et al 2004). Reptilian reovirus is one of a limited number of non-enveloped viruses that are capable of inducing cell-cell fusion (Duncan et al 2004; Corcoran and Duncan 2004). Reoviruses have been identified from many reptile species. (Ahne et al 1987; Vieler et al 1994; Drury et al 2002; Corcoran and Duncan 2004). The green lizard (*Lacerta viridis* LAURENTI 1768) is native to middle and southern Europe and its habitat extends from Thrace to north-west Anatolia and the Black-Sea coastal strip in Turkey (Baran and Atatür 2002). There is no report of reovirus infection in lizards in Turkey and this report describes the first cutaneous lesions with a papillomatous structure associated with Reovirus in a green lizard (*Lacerta viridis* LAURENTI 1768).

MATERIALS AND METHODS

The lizard was anesthetized via ether inhalation and the masses were surgically removed. Removed masses were fixed in 10% neutral formalin, embedded in paraffin and 5 µm sections were cut. Sections were stained with both Hematoxylin-Eosin (HE) and immunohistochemically using the streptavidin-biotin-peroxidase complex method for papilloma virus. As described previously by Ozyigit et al (2007). Specific antiserum used in this study was 1:100 diluted rabbit anti-bovine papilloma polyclonal antibody (Diagnostic Biosystem, Pleasanton, USA). In short, deparaffinized sections were treated with citrate buffer in a microwave oven at 700 Watts for 20 minutes. After washing with phosphate buffered saline, sections were treated with 0.3% H₂O₂ in methanol for 10 minutes to suppress endogenous peroxidase activity, and incubated with 10% normal donkey serum for 15 minutes. The primary antibody was applied at room temperature for 30 minutes. The antibody reaction products were visualized with 3, 3'-diaminobenzidine tetrahydrochloride (Sigma Diagnostic, St. Louis, USA) and counterstained with Hematoxylin. Also the tissues were sent to Department of Pathology, University of Utrecht, The Netherlands, for electron microscopic examination. Briefly, tissue samples from cutaneous warts from the lizard were fixed in glutaraldehyde and 0.1 M phosphate buffer (2%), then post-fixed in 1% osmium tetroxide and then immersed in 0.5% uranyl acetate overnight and dehydrated in increasing concentrations of acetone. The samples were then embedded in Araldite 502. Ultra thin sections were cut in ultra microtome and contrasted with uranyl acetate and lead acetate and photomicrographs were taken.

RESULTS AND DISCUSSION

The lizard was caught in Uludag, Bursa, north-western Turkey. In the macroscopical examination, wart-like growths were seen on the dorsum of the animal on the skin between the forearms and on the back close to the

* Corresponding author: hakk@uludag.edu.tr

pelvic region. Nodular lesions were 2x2 and 5x3 mm in size, hard in consistency and covered with greenish-brown coloured crusts and the lesions were superficial (Figure 1). In the microscopical examination of HE-stained sections, hyperkeratosis and ballooning degeneration were observed. Degenerated epithelial cells contained peripherally located nuclei, and large, ovoid, dense, eosinophilic inclusions in the cytoplasm (Figure 2). There was no positive reaction for papilloma virus in immunohistochemistry. An electron microscopic study of these growths revealed the presence of viral particles, 65 nm in diameter, icosahedral-spherical appearance belonging, to the family *Reoviridae* (Figure 3).




Figure 1. Tumoral growths, greenish-brown coloured crusts on dorsal surface. Consistency of lesions was hard and the lesions were superficial.

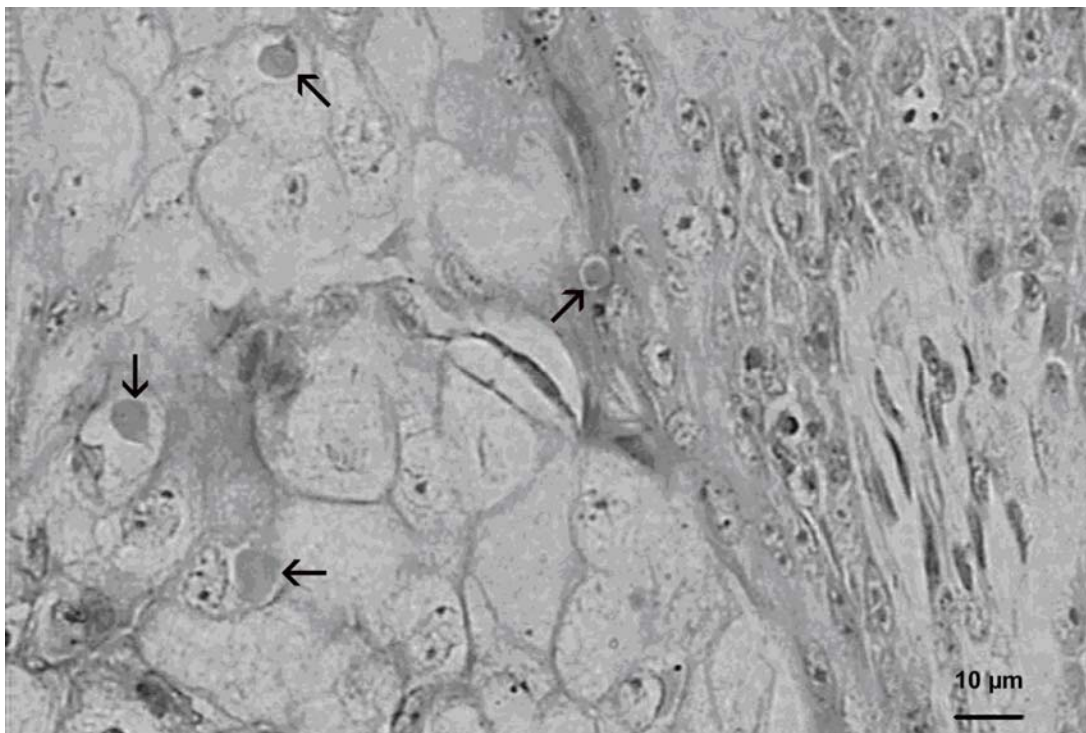


Figure 2. Ballooning degeneration, and large, ovoid, dense eosinophilic intracytoplasmic inclusions in the cytoplasm of the epithelial cells (arrows).

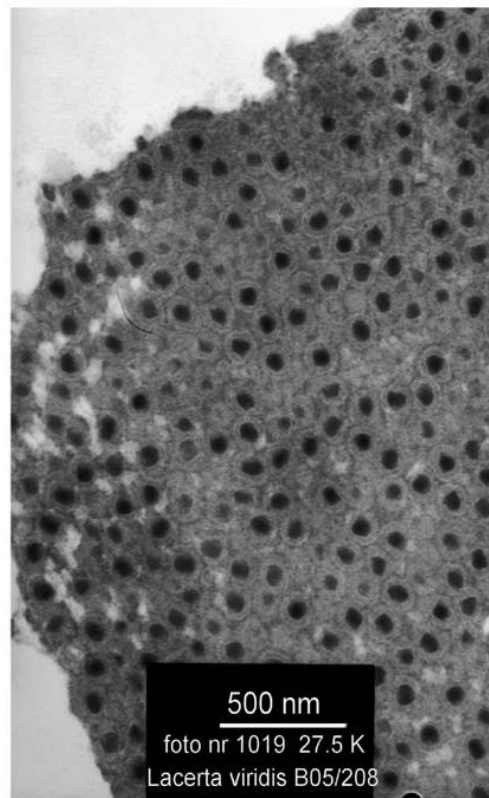


Figure 3. Electron micrograph of a reo-like virus which infected epithelial cells in epidermis.

The isolation and identification of reoviruses from reptiles has become more frequent in recent years (Ahne et al 1987; Vieler et al 1994; Gravendyck et al 1998; Drury et al 2002; Marschang et al 2002; Duncan et al 2004). Virus isolation has been detected by electron microscopy and by virus neutralization tests (Raynaud and Adrian 1976; Gravendyck et al 1998; Drury et al 2002; Marschang et al 2002). Electron microscopically, in intestinal tissues from a tortoise, *Geochelone pardalis*, in faeces from a chameleon, *Chameleo quadricornis*, in skin from green lizards, *Lacerta viridis*, in liver spleen and small intestinal tissue in lizards, *Uromastyx hardwickii* were detected (Raynaud and Adrian 1976; Drury et al 2002; Marschang et al 2002).

Antibodies to reptilian reoviruses in blood in Mexican lizards, *Xenosaurus* and *Abronia* spp., Spiny-tailed iguanas, *Ctenosaura bakeri*, *C. similis* and Green iguanas *Iguana iguana rhinolopha* were also detected (Gravendyck et al 1998; Marschang et al 2002). Isolation of reoviruses from various reptiles has been reported (Ahne et al 1987; Vieler et al 1994; Jacobson 1998). Numerous papillomatous growths affecting the skin of the dorsal part of the body were revealed as Herpes, Reo and Papova virus by electron microscopic study in a population of *Lacerta viridis* reared in laboratory (Raynaud and Adrian 1976). We confirmed the aetiology in this case as reovirus depending on the electron microscopic examination.

REFERENCES

- Ahne W, Thomsen I, Winton J (1987). Isolation of a reovirus from the snake, *Python regius*. Arch Virol 94:135-139.
- Baran İ, Atatür MK (1998). Turkish Herpetofauna (Amphibians and Reptiles). Republic of Turkey Ministry of Environment Press, Ankara.
- Corcoran JA, Duncan R (2004). Reptilian reovirus utilizes a small type III protein with an external myristylated amino terminus to mediate cell-cell fusion. J Virol 78:4342
- Drury SEN, Gough RE, Welchman DB (2002). Isolation and identification of a reovirus from a lizard, *Uromastyx hardwickii*, in the United Kingdom. Vet Rec 151:637
- Duncan R, Corcoran J, Shou J, Stoltz D (2004). Reptilian reovirus: a new fusogenic orthoreovirus species. Virol 319:131-140.
- Gravendyck M, Ammermann P, Marschang RE, Kaleta EF (1998). Paramyxoviral and reoviral infections of iguanas on Honduran Islands. J Wildl Dis 34:33-38.
- Jacobson ER (1986). Viruses and viral associated diseases of reptiles. Acta Zool Pathol Antverp 79:73-90.

- Marschang RE, Donahoe S, Manvell R, Lemos-Espinal J (2002). Paramyxovirus and reovirus infections in wild-caught Mexican lizards (*Xenosaurus* and *Abronia* spp.) J Zoo Wildl Med. 33: 317-321.
- Özyiğit MÖ, Şentürk S, Akkoç A (2007). Suspected Congenital Generalized Tuberculosis in a new-born Calf. Vet Rec, 160(9): 307-308.
- Raynaud A, Adrian M (1976). Cutaneous lesions with a papillomatous structure associated with viruses in the green lizard (*Lacerta viridis*). CR Acad Sci D Sci Nat, 283: 845-847.
- Vieler E, Baumgartner W, Herbst W, Kohler G (1994). Characterisation of a reovirus isolates from a rattle snake, *Crotalus viridis*, with neurological dysfunction. Arch Virol 138: 341-344.